



ORIGINAL RESEARCH PAPER

General Surgery

A STUDY OF PRESENTATION AND MANAGEMENT OF 30 CASES OF COMPLICATED AMOEBIC LIVER ABSCESS

KEY WORDS: Amoebic liver abscess, Complications, Interventions.

Dr. Bina Vaidya	Additional professor in department of general surgery, Government medical college, Surat.
Dr. Tejas Patel	Assistant professor in department of general surgery, Government medical college, Surat.
Dr. Chirag Tulsyani*	Resident doctor in department of general surgery, Government medical college, Surat. *Corresponding Author
Dr. Prabhuta Khare	Resident doctor in department of general surgery, Government medical college, Surat.

ABSTRACT

BACKGROUND AND AIMS: Liver abscess and its complications both can have its serious implications if presented late. Complication of liver abscess forms the major cause of morbidity and mortality especially in a developing country like India. Early detection of complications with use of modern radiological modalities and its appropriate management can reduce the associated morbidity and mortality.

METHODS : A Case series of 30 patients with ruptured liver abscess with clear signs of peritonitis(generalized guarding and rigidity) or pleural cavity rupture(breathlessness, chest pain, cough with expectoration) were included in study. A preformed protocol for management was followed for all the patients and accordingly various surgical interventions were considered in the patients.

RESULTS: In this study of 30 patients, majority of affected were male (80%) with most common affected age group of 30-60 years. Most common presentation was Localized tenderness over right hypochondrium(100%). In patients with peritoneal or pelvic cavity rupture, generalized guarding and rigidity (86%) and in patients with pleural cavity rupture - chest pain, breathlessness or cough with expectoration (20%) is the common presentation. Most of the patients were managed with surgical exploration in the form Laparotomy with peritoneal lavage, laparoscopic drainage, intercostal drain placement and thoracotomy with decortication.

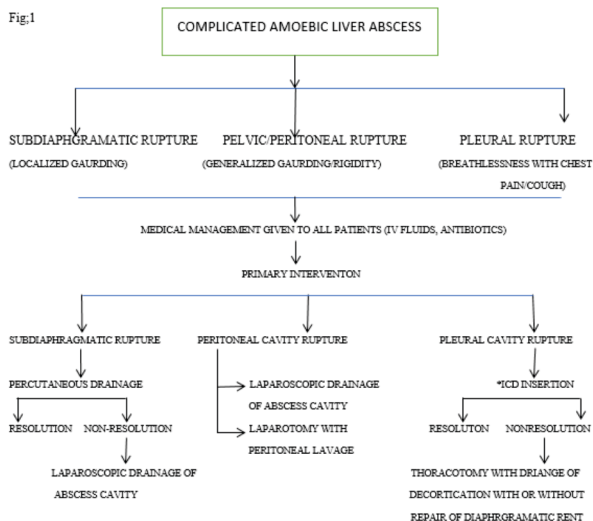
CONCLUSION: In our study we have found that complications of liver abscess needs early surgical intervention to reduce morbidity and mortality associated with complicated liver abscess.

INTRODUCTION

Liver abscess can be classified into pyogenic and amoebic liver abscess; both can have its serious implications if presented late. Complications of Amoebic liver abscess forms the major cause of morbidity and mortality especially in a developing country like India². The most common complications of amoebic liver abscess arise from rupture of abscess into surrounding organs or anatomic spaces². Peritoneal and visceral involvement may show adherence of liver abscess to the diaphragm, abdominal wall, omentum, or bowel tends to confine contamination and lead to rupture into the hollow viscera, such as the stomach or colon². A hepatogastric, hepatoduodenal or hepatocolic fistula and acute hepatic failure may occur³. Other complications of amoebic liver abscess are thoracic and pleuropulmonary involvement, Vascular and pericardial involvement. Early intervention with use of modern radiological investigation can reduce the associated morbidity and mortality. We have included the following cases in our study as Complicated Amoebic liver Abscess; patients with rupture into subdiaphragmatic cavity, rupture into peritoneal and pelvic cavity and pleural cavity.

MATERIALS AND METHOD

A study of 30 patients of complicated amoebic liver abscess was conducted from May 2016- September 2019 in Government medical college, Surat. All the patients were subjected to routine blood investigations and radiological investigations like X-ray chest and X-ray abdomen standing and ultrasonography of thorax and abdomen and in some patients C-T-thorax was done. Based on clinical findings and radiological investigations patients with complicated amoebic liver abscess were taken into consideration. The patients were treated as discussed in fig1



*ICD= INTERCOSTAL DRAINAGE TUBE

RESULTS AND ANALYSIS

In our study of 30 patients, the most commonly affected were males (80%) and most common affected age group was between 30-40 years (table: 1). Most common complication was rupture into pelvic and peritoneal cavity (65%) (table: 2). Percutaneous drainage was done in 4 patients, laparoscopic drainage and peritoneal lavage in 8 patients, exploratory laparotomy with peritoneal lavage in 14 Patients, Thoracotomy with drainage of abscess cavity with decortication with or without repair of diaphragmatic rent in 4 Patients (table: 3). In Patients with subdiaphragmatic rupture maximum hospital stay was 12 days with average stay of 8

days as some patients with nonresolution required laparoscopic drainage. Patients with rupture into pelvic and peritoneal cavity had prolonged hospital stay – maximum 45 days with average stay of 22 days because of complications like paralytic ileus and wound infection. In Patients with rupture into pleural cavity maximum stay was 25 days with average stay of 17 days as these patients were managed by thoracotomy with decortication with postoperative ventilatory support and wound infection was in 6 Patients (20%).

Table: 1 Distribution of age, sex, clinical features

	No of patients
Median age	30-40 years
Sex (male :female)	24:6
Right hypochondrial pain/tenderness	30(100%)
Fever with chills/rigor	23(77%)
Loss of appetite	20(66%)
Generalized guarding and rigidity	26(87%)
Breathlessness with chest pain/cough	6(20%)

Table: 2 Complications in amoebic liver abscess

Complications	No of patients
Sub diaphragmatic rupture	6(20%)
Peritoneal/pelvic rupture	20(65%)
Pleural cavity rupture	4(14%)

Table: 3 Interventions in complicated amoebic liver abscess

Intervention	No of patients
Percutaneous drainage	4(14%)
Intercostal drain insertion	2(6%)
Exploratory laparotomy with Peritoneal lavage	12(40%)
Laparoscopic drainage of Abscess cavity	8(26%)
Thoracotomy with abscess drainage with decortication	4(14%)

DISCUSSION

The overall mortality of uncomplicated amoebic liver abscess is 1% and in complicated amoebic liver abscess is 6 -50%¹. Our study shows overall mortality of 4%. Spontaneous rupture of amoebic liver abscess is 2.7% to 17% of cases¹ and pulmonary complications occur in 7% to 20% of patients². Rupture of abscess cavity into pericardium is rare but serious, occurring in 1.3% to 2% patients⁴. Patients with subdiaphragmatic rupture were primarily intervened by percutaneous drainage of abscess cavity, upon nonresolution these patients were managed by laparoscopic drainage of abscess cavity. Patients intervened by laparotomy/ laparoscopic drainage did not require any further surgical intervention. The patients with rupture into pleural cavity were primarily intervened by intercostal drain insertion some of these patients showed complete resolution of abscess cavity while others who didn't show improvement upon tube insertion were subjected to ultrasonography of abdomen and thorax along with computed tomography of thorax. Patients with nonresolution of abscess cavity and collapsed lung were managed by thoracotomy with decortication and with or without diaphragmatic rent repair. Some patients who had pleural, peritoneal/pelvic cavity rupture required post-operative ventilatory support, some suffered from postoperative paralytic ileus and wound infection due to which their hospital stay was prolonged. Patients managed by laparoscopic drainage of abscess cavity have early ambulation and no associated morbidity.

CONCLUSION

Complicated Amoebic Liver abscess is a surgical challenge which needs to be addressed in early stage of disease progression. Timely surgical interventions along with medical management can reduce the associated morbidity and mortality in amoebic liver abscess. Ineffective drainage of amoebic empyema is usually complicated by secondary

infection that requires aggressive surgical procedure like thoracotomy with decortication with postoperative ventilatory support and has prolonged hospital stay. Laparoscopic drainage of abscess cavity with peritoneal lavage has better postoperative result; these patients have early ambulation and few postoperative complications. Based on the general condition of patient and available resources complications of amoebic liver abscess has to be timely managed by medical and various surgical interventions.

REFERENCES

1. Hany Dabbous, Hosein Shokouh-Amiri, and Gazi B 73:1083-1091, Blumgart's surgery of liver, pancreas, biliary tree, 6th edition.
2. Ken JG, et al: Perforated amoebic liver abscesses: successful percutaneous treatment, Radiology 170:195-197, 1989.
3. Angel C, et al: Gastric wall erosion by an amoebic liver abscess in a 3-year-old girl, Pediatr Surg Int 16:429-430, 2000.
4. Rao S, et al: Hepatic amoebiasis: a reminder of the complications, Curr Opin Pediatr 21:145-149, 2009.
5. Shamsuzzaman SM, Hashiguchi Y: Thoracic amoebiasis, Clin Chest Med 23:479-492, 2002.
6. Stanley SL Jr: amoebiasis, lancet 361:1025-1034, 2003.