



ORIGINAL RESEARCH PAPER

Orthodontics

ORTHOPEDIC - ORTHODONTIC PROTOCOL OF PREMAXILLA MANAGEMENT, IN PATIENTS WITH BILATERAL CLEFT.

KEY WORDS: BILATERAL CLEFT LIP AND CLEFT PLATE, PREMAXILLA, PROTOCOL, ORTHODONTIC-ORTHOPEDIC TREATMENT.

Cynthia Dabed

Orthodontist In Fundación Gantz, Santiago, Chile.

Daniela Romero*

Dentist. Intern in Orthodontic Unit, Fundación Gantz. *Corresponding Author

Luz M. Searle

Dentist. Intern in Orthodontic Unit, Fundación Gantz.

ABSTRACT

The alveolar cleft is a bone defect of the dentoalveolar area of the upper arch, which affects approximately 75% of patients with cleft. There are many protocols for orthopedic - orthodontic treatment, generating controversy regarding the timing of treatment, the technique and the type of equipment used.

This protocol in patients with bilateral cleft lip and palate shows the steps of orthopedic - orthodontic treatment in the different dentitions. The objectives are to expand the maxilla, align and level the premaxilla with the maxillary segments, reduce the width of the cleft and establish a normal relationship between the upper and lower jaw. Minimizing the impact that this malformation has on the quality of life of patients.

This paper aims to inform the different professionals dealing with children with bilateral cleft lip and palate about the nature of this congenital malformation and guide them through the orthodontic and orthopedic phases.

INTRODUCTION

The most common craniofacial malformation that an orthodontist can face is the cleft lip and palate.¹ This constitutes a congenital structural deficiency, due to the lack of fusion between the maxillary processes.²

In bilateral patients, the reconstruction of the anatomy of the nose, lip and palate, as well as achieving the symmetry of these structures is highly complex. Therefore, it is important to understand the etiology and dynamics of growth and development, the separation of the vomer and premaxilla (as a unit) from the rest of the maxilla, is a very important aspect.³

The American Cleft Palate-Craniofacial Association was founded in 1943, to support patients with lip and / or palatal cleft and their families. This association defined the role of the Orthodontist within the multidisciplinary team and found that teamwork is essential for the treatment of these patients with orofacial fissures.⁴

ORTHODONTIST ROLE

Orthopedic - orthodontic treatment in patients with cleft lip and palate is important within the interdisciplinary care that these patients receive.

The objectives of this orthopedic-orthodontic treatment are to expand the jaw if it is compressed, then align and level the premaxilla with the maxillary segments. Thus, the width of the alveolar cleft is reduced and a normal relationship between maxilla and mandible is established. In addition to achieving a better aesthetic result and normal speech development. However, at different stages of the dentition, patients with complete bilateral fissure may present with a displaced premaxilla, presenting a wide alveolar fissure, which can be a problem for orthodontists and surgeons⁵ when establishing the appropriate time to perform the bone graft surgery. Therefore, due to its level of complexity it is necessary that the treatment is always individualized and reevaluated at each stage.

The final objective of the Orthodontist's work within the interdisciplinary team that treats patients with bilateral cleft is to achieve a good aesthetic result, a normal development of speech with minimal alteration in facial skull growth.⁶

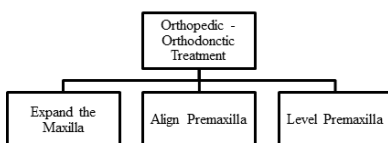


Table 1: Concept map of orthopedic - orthodontic treatment principles for patients with bilateral cleft lip and palate.

ALTERATION OF THE PREMAXILLA IN COMPLETE BILATERAL CLEFT

The most common alteration in patients with bilateral fissure is a prominent, protruded and extruded premaxilla. Other positions of the premaxilla can be: destroyed, intruded, rotated, diverted to the right or left. In terms of size, can be a large premaxilla with 3 to 4 incisors, a small premaxilla with 1 to 2 incisors or a normal size premaxilla. Depending on the position and size of the premaxilla, the width of the cleft varies, being able to find an overjet and increased overbite.

Several studies indicated that the prominence of premaxilla decreases during the growth period and gradually resolves into adulthood. Therefore, it is recommended to leave premaxilla untreated until that age. However, leaving this altered position of the premaxilla unresolved until permanent dentition can complicate and delay alveolar bone graft surgery. In addition, it can affect the patient psychologically.⁷

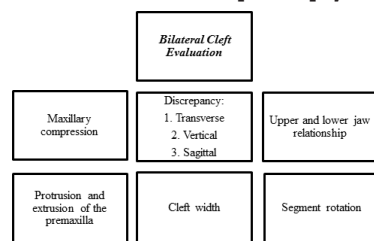


Table 2: Concept map of extraoral and intraoral aspects that must be evaluated in order to plan treatment in patients with bilateral cleft lip and palate.

TREATMENT OF PREMAXILLA IN PATIENTS WITH COMPLETE BILATERAL CLEFT

The timing of orthodontic treatment can be evaluated in three periods. In these periods certain objectives must be achieved.

- Primary dentition.
- Mixed dentition.
- Permanent dentition.

PRIMARY DENTITION

In patients with bilateral cleft lip and palate, compression of the posterior sectors is manifested with a bilateral cross bite and a protrusion and extrusion of the premaxilla. In this case, it

would be necessary to carry out the expansion of the posterior sectors, uncovering the bite.

The Orthodontist must evaluate various factors when starting orthodontic treatment, in the primary dentition. These factors are: the cooperation of the patient, the commitment of the parents, the severity of their malocclusion, the moment in which the bone graft is to be performed and the need for orthodontic treatment in the future.

In these cases, the appliance used is an acrylic device with planes and with a central expansion screw, which is cemented. Its purpose is to reposition the lateral segments that are compressed. If the compression is rather previous, anterior expansion is done with fan screw. The device must be activated once a day, expanding ¼ turn. The amount of expansion depends on each patient according to their study of models. After one month, after expanding and uncrossing the bite, the premaxilla leveling begins in relation to the lateral segments by using a removable anterior plane in the lower arch. The duration of this stage of expansion and leveling is approximately one year. Once these two stages have been completed, containment must be left for a long time. This is due to the fact that there is no palatine closure, so the expansion recurred more. Also for the waiting time for bone grafting.

MIXED DENTITION

In the period of mixed dentition, skeletal and occlusal problems, including dental anomalies of number, shape and position of the teeth, must be evaluated in order to establish a treatment plan.

In this stage the first permanent molars are already erupted, which can help to achieve the alignment and leveling of the permanent upper incisors with brackets, and thus of the premaxilla. Also, a transpalatal arch can be used, which helps maintain expansion and stabilize the maxillary segments, as an anchor unit for the premaxilla intrusion.⁸ At early ages, the alignment of the premaxilla often occurs spontaneously, then of the expansion.

Orthodontics in this period has two phases:

Pre - graft phase

The objective of this phase is to perform the 3 steps of the protocol, to prepare the patient for bone graft surgery. First, correct the cross bite by expansion, so the treatment should begin several months before placing the graft. The upper jaw is usually compressed, so it may have a posterior cross bite. If the compression is greater in the anterior area, the typical "V" palate can be observed. The expansion devices of the upper jaw can be anchored on the first permanent molars and can be quad helix, circuit breaker performing a rapid or slow expansion.⁹ The minimum use time of these devices is 7 months, the first month is activation and the subsequent 6 months are contained with the same expansion device. After one month of treatment, begin to align and then level the incisors with brackets ideally. Then, a palatal bar can be used for containment. If the roots of the incisors still do not have an apical closure, a removable device can be used to align upper incisors and lower plane to align the premaxilla

Ideally, place the graft when the canine has not yet erupted, ideally when the development of the canine root is 1/3 to 2/3. Thus, it is generally possible for the canine to erupt normally in a large number of cases. In addition, the formation of additional bone is favored. While bone graft surgery is not performed, the lower plane should be used to level the premaxilla, this plane is used at night, preventing the premaxilla from being extruded. Since the bone graft stabilizes the premaxilla.

Post - graft phase

Once the bone graft is performed, at the end of the surgery, a Splint (acrylic stamping) is left for approximately 6 weeks, to prevent the movement of the premaxilla. And the use of the lower plane is discontinued. Since it is recommended to perform the surgery on one side and after the other. Orthodontic treatment in the upper arch is resumed 6 months after the bone graft. Meanwhile, the bone graft is controlled, avoiding any type of trauma in the grafted area to achieve its consolidation, further progress can be made with the treatment in the lower arch, if necessary. Once the surgical phase has been completed, the definitive upper canines may erupt through the graft area.

PERMANENT DENTITION

During permanent dentition, the patient requires Orthodontics, although previously treated, because it usually presents a complex malocclusion and altered occlusion. Frequently, there is a cross bite because it was not previously corrected or because it recurred. Therefore, the first thing that is done is the maxillary expansion. This is possible at any age, since there is no bone closure.¹⁰

At this stage the treatment plan focuses on aligning, intruding the premaxilla, and leveling the arches, obtaining a good relationship between them, stabilizing the occlusion and improving the aesthetics, by means of fixed appliances, and if the use of a lower plane is necessary.¹¹

In some cases, the indicated treatment will be exclusively Orthodontics and in others it will have to be complemented with Orthognathic Surgery, once the maxillofacial growth has concluded.

PROGRESS AND PROGNOSIS DEPENDS ON TWO FACTORS:

- **INTRINSIC:** on the one hand, the severity of the malformation and its association with other alterations and the unpredictable growth retardation, which determines the malformation itself and eventually its treatment.
- **EXTRINSIC:** fundamentally the quality of the treatment received, which in turn is greatly influenced by socio-economic determinants on which it is difficult to act. The absence of controls and hygiene problems. Some studies have related a poor quality of treatment with the absence of therapeutic protocols, fragmented actions, lack of adequate follow-up (until the end of growth) and poor experience of the therapeutic team.¹²

REFERENCES

1. Heidbuchel KL, Kuijpers-Jagtman AM, Van't Hof MA. Effects of early treatment on maxillary arch development in BCLP. A study on dental casts between 0 and 4 years of age. *J Craniomaxillofac Surg* 1998;26:140-147.
2. El-Kassaby MA, Abdelrahman NI, Abbass IT. Premaxillary characteristics in complete bilateral cleft lip and palate: a predictor for treatment outcome. *Ann Maxillofac Surg* 2013;3:11-19.
3. Seo YJ, Park JW, Kim YH, et al. Initial growth pattern of children with cleft before alveolar bone graft stage according to cleft type. *Angle Orthod* 2011;81:1103-1110.
4. Koussseff B, Papehausen P, Neu R, Essig Y, Saraceno C. Cleft palate and complex chromosome rearrangements. *Clin Genet* 1992;42(3):135-42.
5. Shapira Y, Lubit E, Kufnec M. The distribution of clefts of the primary and secondary palates by sex, type and location. *Angle Orthod* 1999;69(6):523-8.
6. Koh KS, Kim H, Oh TS et al. Treatment algorithm for bilateral alveolar cleft based on the position of the premaxilla and the width of the alveolar gap. *J Plast Reconstr Aesthet Surg*. 2013; (66): 1212-1218.
7. Latief BS, Lekkas C, Kuijpers MA. Maxillary arch width in unoperated adult bilateral cleft lip and alveolus and complete bilateral cleft lip and palate. *Orthod Craniofac Res* 2010;13:82-88.
8. Mihee H, Seung-Hak B. Parameters for evaluation and treatment of patients with cleft lip/palate or other craniofacial anomalies. *American Cleft Palate-Craniofacial Association. Cleft Palate Craniofac J* 1993;30(Suppl 1):S1-S16.
9. Lino M, Sasaki T, Kochi S. New orthodontic and orthopaedic managements on the premaxillary deformities in patients with bilateral cleft before alveolar bone grafting. *Cleft Palate-Craniofac J*. 1998;35:304-9.
10. Trotman C, Ross R. Craniofacial growth in bilateral cleft lip and palate: ages six years to adulthood. *Cleft Palate-Craniofac J*. 1993;30:261-73.

11. Saltaji H, Major M, Altalibi M, Youssef M, Flores-Mir C. Longterm skeletal stability after maxillary advancement with distraction osteogenesis in cleft lip and palate patients. *Angle Orthod* 2012;82(6):1115-22.
12. Jaiswal A, Jaiswal R, Neela P. Paradigm of correcting vertical premaxillary descent in BCLP patients with accentuated curve niti wires. *Journal of Contemporary Orthodontics*.2017;1(3):32-36.