



ORIGINAL RESEARCH PAPER

Oncology

PEMBROLIZUMAB INDUCED PNEUMONITIS EXPERIENCE IN A HOSPITAL OF QUITO-ECUADOR

KEY WORDS:

María Herrera Herrera	General Practitioner
Santiago Almeida Pinto*	General Practitioner *Corresponding Author
Christian Aguilar Erazo	General Practitioner
Diana Tolagasí Quilumba	General Practitioner
Ana Pachacama Barros	General Practitioner
Andrés Benavides Zúñiga	General Practitioner
Darwin Cortez Palma	General Practitioner
Valeria Naranjo Benavides	General Practitioner

ABSTRACT

Immunotherapy-induced pneumonitis is a complication present in 3% in patients with non-small cell lung cancer based on this treatment, being the same difficult to diagnose even more in a country that is not in international experience, In this review we want to present our experience with the first patient treated with pembrolizumab in our institution.

INTRODUCTION

Immunotherapy-induced pneumonitis is a complication present in approximately 3% of patients treated with non-small cell lung cancer, being a difficult complication to diagnose and a challenge for both the oncologist and the pulmonologist who begins using it. (1-6)

It must be recognized that immunotherapy has shown significant increases in the survival of patients with lung cancer in advanced stages, with programmed cell death protein 1 (PD-1) being a transmembrane T-cell inhibitor, thus having Pembrolizumab and Nivolumab as monoclonal antibodies cells that bind to the PD-1 receptor in T cells and thus block their binding to the PDL-1 ligand in tumor cells. (2,7,8)

The response of these T cells, the result of the inhibition of the control point, can lead to an unusual spectrum of side effects called adverse events related to the immune system involving skin, liver, lungs, endocrine system among others. (8-12)

Immunotherapy-induced pneumonitis is a potentially fatal effect that occurs in 1-5% of patients enrolled in the studies. (12)

In Quito, the first case treated took place in January 2017, for which we express our experience.

CASE REPORT

47-year-old male patient, Karnofsky 70, non-smoker with no

personal pathological history or story of medication intake, who has presented approximately 3 kg of weight loss in 2 months ago accompanied by cough with hemoptysis.

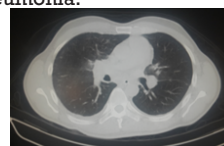
Chest tomography reports a mass in the left upper lobe of 5.7 x 4cm, plus a 6 cm diameter mediastinal conglomerate.

Bronchoscopy reports in the left bronchial tree, basal bronchus, anterior segment, presence of abundant active bleeding, infiltrative mucosa with irregular borders.

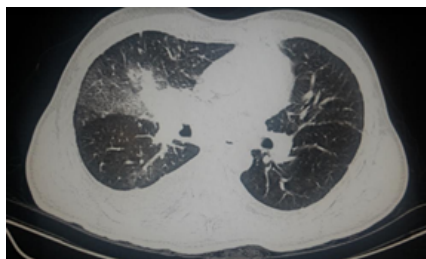
The histopathological sample reported: non-small cell adenocarcinoma, non-mutated EGFR, non-rearrangement of ALK and PDL-1 expression greater than 50%.

The PET / SCAN reported diffuse bone activity in the spine, pelvis and femurs, similar bone scintigraphy report and MRI Brain negative for metastatic activity.

As a treatment, he receives 30 Gys palliative radiotherapy on the lumbar spine and pelvis, then starts Pembrolizumab at a dose of 200 mg IV every 21 days, receives 3 treatment cycles with a favorable clinical response, after the fourth cycle, attends with a cough, respiratory distress ; clinical suggestive pneumonitis vs pneumonia.



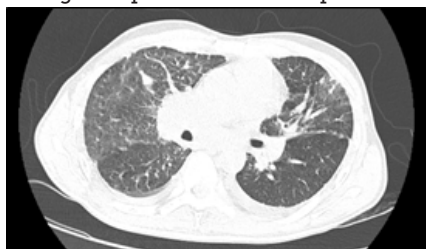TAC POST THIRD CYCLE: stability of tumor lesion



Emergency tomography after the third cycle shows infiltration in frosted glass.

During hospitalization, the patient remains afebrile with a report of negative inflammatory markers and negative sputum.

It is classified as grade 3 immunotherapy pneumonitis, fifth cycle of Pembrolizumab is suspended and prednisone is started at a dose of 1mg / kg / day, gradually decreasing the dose according to the patient's clinical response.



Resolution of pneumonitis symptoms after corticosteroid use

Three months after the use of corticosteroids, the patient dies identifying enterobacter cloacae in a sputum sample taken in emergency at the date of new care.

DISCUSSION

By Vincent Leroy, et al. Little is known about the factors that promote pneumonitis in patients treated with anti-PD-1 antibodies, but it does not appear to be related to the dose of antibodies, pneumonitis occurs most frequently in patients with a history of asthma / chronic obstructive pulmonary disease and more frequently in patients with a history of thoracic radiation (6.0% versus 2.6%). Therefore, pneumonitis may be facilitated by pre-existing local inflammation. Adverse events related to immunity are usually treated with immunomodulatory medications, with steroids as the first line of treatment.(13)

By Qioang Su et al, The precise pathophysiology of the differences between PD1 / PDL-1 inhibitors and CTL-4 inhibitors has not yet been discovered, pneumonitis involves effector and regulatory T cells deregulated in the pulmonary interstitium, which ultimately leads to an inflammatory response, some studies have shown that PD-1 inhibitors have more potential to activate T cells towards a broad spectrum of antigens. tissue-specific, including pulmonary parenchyma, that CTLA-4 inhibitors, Pneumonitis involves effector and regulatory T cells deregulated in the pulmonary interstitium, which ultimately leads to an inflammatory response, some studies have shown that PD-1 inhibitors have more potential to activate T cells towards a broad spectrum of antigens. tissue-specific, including pulmonary parenchyma, that CTLA-4 inhibitors, PD-L1 inhibitors appear to have a less severe immune system-induced toxicity than PD-1 inhibitors, in part because PD-L1 blockages do not prevent interactions between PD-L2 and PD-1. PD-L2 could mediate pneumonitis by increasing the interaction with RGMb (repulsive guide molecule B) expressed by interstitial lung macrophages and alveolar cells, resulting in a clonal expansion of local T

cells.(1-3,5,10-12,14,15)

In conclusion, pneumonitis secondary to PD1 / PDL1 inhibitor drugs is a rare but potentially serious adverse effect, so it must be ruled out in the presence of respiratory symptoms in these patients, a radiological pattern in which frosted glass is observed that in the first instance made think of pneumonia, but the rapid identification and handling with oral corticosteroids were fundamental for the resolution of the picture.

REFERENCES

1. KADONO T. Immune-related adverse events by immune checkpoint inhibitors. Japanese J Clin Immunol [Internet]. 2017;40(2):83-9. Available from: https://www.jstage.jst.go.jp/article/jsci/40/2/40_83/_article/-char/ja/
2. Cousin S, Italiano A. Molecular Pathways: Immune Checkpoint Antibodies and their Toxicities. Clin Cancer Res [Internet]. 2016 Sep 15;22(18):4550-5. Available from: <http://clincancerres.aacrjournals.org/cgi/doi/10.1158/1078-0432.CCR-15-2569>
3. Horio Y. Management of toxicities of immune checkpoint inhibitors. Japanese Journal of Cancer and Chemotherapy. 2017.
4. Sul J, Blumenthal GM, Jiang X, He K, Keegan P, Pazdur R. FDA Approval Summary: Pembrolizumab for the Treatment of Patients With Metastatic Non-Small Cell Lung Cancer Whose Tumors Express Programmed Death-Ligand 1. Oncologist [Internet]. 2016 May;21(5):643-50. Available from: <http://theoncologist.alphamedpress.org/lookup/doi/10.1634/theoncologist.t.2015-0498>
5. Ueno R, Nemoto M, Uegami W, Fukuoka J, Misawa M. Pembrolizumab-induced pneumonitis with a perilymphatic nodular pattern in a lung cancer patient: A radio-pathologic correlation. Respir Med Case Reports [Internet]. 2019;26:168-70. Available from: <https://linkinghub.elsevier.com/retrieve/pii/S2213007118303551>
6. Leroy V, Templier C, Faivre J-B, Scherpereel A, Fournier C, Mortier L, et al. Pembrolizumab-induced pneumonitis. ERJ Open Res [Internet]. European Respiratory Society; 2017 Apr 1;3(2):00081-2016. Available from: <http://openres.ersjournals.com/lookup/doi/10.1183/23120541.00081-2016>
7. Naidoo J, Page DB, Wolchok JD. Immune Checkpoint Blockade. Hematol Oncol Clin North Am [Internet]. 2014 Jun;28(3):585-600. Available from: <https://linkinghub.elsevier.com/retrieve/pii/S0889858814000173>
8. Peris BH, Coloma JH, Pérez RAA, Gómez C, Miguel L, Esteve S, et al. NEUMONITIS SECUNDARIA A INHIBIDORES DE PD1 EN PACIENTES CON CARCINOMA NO MICROCÍTICO DE PULMÓN. REVISIÓN A PROPOSITO DE UN CASO. GIDO Post [Internet]. 2017;2:1-9. Available from: <https://gido.es/post/2017/08/01/neumonitis-secundaria-a-inhibidores-de-pd1-en-pacientes-con-carcinoma-no-microcitico-de-pulmon-revision-a-proposito-de-un-caso/>
9. Marin-Acevedo JA, Chirila RM, Dronca RS. Immune Checkpoint Inhibitor Toxicities. Mayo Clin Proc [Internet]. 2019 Jul;94(7):1321-9. Available from: <https://linkinghub.elsevier.com/retrieve/pii/S0025619619302757>
10. Champiat S, Lambotte O, Barreau E, Belkhir R, Berdelou A, Carbone F, et al. Management of immune checkpoint blockade dysimmune toxicities: a collaborative position paper. Ann Oncol [Internet]. 2016 Apr;27(4):559-74. Available from: <https://academic.oup.com/annonc/article-lookup/doi/10.1093/annonc/mdv623>
11. Weber JS, Yang JC, Atkins MB, Disis ML. Toxicities of Immunotherapy for the Practitioner. J Clin Oncol [Internet]. 2015 Jun 20;33(18):2092-9. Available from: <http://ascopubs.org/doi/10.1200/JCO.2014.60.0379>
12. Naidoo J, Page DB, Li BT, Connell LC, Schindler K, Lacouture ME, et al. Toxicities of the anti-PD-1 and anti-PD-L1 immune checkpoint antibodies. Ann Oncol. 2015;
13. Leroy V, Templier C, Faivre J-B, Scherpereel A, Fournier C, Mortier L, et al. Pembrolizumab-induced pneumonitis. ERJ Open Res [Internet]. 2017 Apr;3(2):00081-2016. Available from: <http://openres.ersjournals.com/lookup/doi/10.1183/23120541.00081-2016>
14. Su Q, Zhu EC, Wu J, Li T, Hou Y, Wang D, et al. Risk of Pneumonitis and Pneumonia Associated With Immune Checkpoint Inhibitors for Solid Tumors: A Systematic Review and Meta-Analysis. Front Immunol [Internet]. 2019 Feb 4;10(FEB). Available from: <https://www.frontiersin.org/article/10.3389/fimmu.2019.00108/full>
15. Ahn M-J, Gandhi L, Hamid O, Hellmann MD, Garon EB, Ramalingam SS, et al. 459Risk of pneumonitis in patients with advanced NSCLC treated with pembrolizumab in KEYNOTE-001. Ann Oncol [Internet]. 2015 Dec 19;26(suppl 9):ix140.3-ix140. Available from: <https://academic.oup.com/annonc/article-lookup/doi/10.1093/annonc/mdv532.43>