



ORIGINAL RESEARCH PAPER

Cardiology

COMPLETE HEART BLOCK IN AWMI: REVASCULARISATION OR PACEMAKER IMPLANTATION

KEY WORDS: complete heart block, angioplasty, left anterior descending artery

Kalyan Munde	Associate Professor, Department of cardiology, Grant Medical College, Mumbai
Rohit Rai*	Senior Resident, Department of cardiology, Grant Medical College, Mumbai *Corresponding Author
Shakil Shaikh	Assistant Professor, Department of cardiology, Grant Medical College
Aditya Gupta	Senior Resident, Department of cardiology, Grant Medical College

ABSTRACT

Complete heart block can be either congenital or acquired. Among acquired causes common ones are drugs, degenerative diseases, infectious causes, rheumatic diseases, infiltrative processes, neuromuscular disorders, ischemic causes, metabolic causes, toxins and iatrogenic causes. RCA occlusion has high incidence of AV block which resolves promptly after revascularization. AV block in the setting of LAD territory occlusion has a more ominous prognosis. We revascularized LAD and prevented the implantation of Pacemaker

INTRODUCTION:

Complete heart block is a known complication of inferior wall myocardial infarction and occurs in 20% of patients with inferior wall myocardial infarction^[1] Complete heart block has also been reported following PTCA of LAD following occlusion of first septal perforator by 'snow ploughing' effect^[2-5] Incidence of complete heart block in myocardial infarction has been reported to be 3-13% in pre thrombolysis and reperfusion era^[6] reduced to 2.2% in a recent study^[7] Mortality is also higher in patients developing CHB with MI^[8]

Case:

A 56 years old male presented with recurrent episodes of syncope for 2 days and breathlessness on exertion for 1 day. His pulse rate on admission was 44/min and BP = 120/80 mmHg. On physical examination, general examination, cardiovascular system, nervous and respiratory system examination revealed no significant abnormality. ECG revealed qRBBB pattern with AV dissociation (figure 1). Echocardiography showed basal, mid and distal anterior anterolateral and anteroseptal walls were hypokinetic. In cardiac enzymes troponin I was significantly raised 21.8(0-1.0 ng/ml), TSH was raised 10.99(0.34-5.6 micro IU/ml), among electrolytes sodium was 131.66 meq/Lt, potassium was 3.39 meq/Lt, calcium was 8.8 mg%, magnesium was 2.08 mg/dl. Serum creatinine was 1.0 mg% on admission.

Temporary pacemaker was inserted and patient symptoms improved. Patient was taken for angiography which revealed LAD after D1 99% lesion (Figure 2 and 3). Patient was immediately taken for angioplasty and lesion stented with drug eluting stent 3.5 x 33 mm in size (figure 4). Check shoot suggestive of TIMI III flow with no evidence of flap/dissection (figure 5).

Patient stable post procedure shifted to ICCU. ECG showed self rhythm with left bundle branch block pattern (figure 6). TPI lead was removed after 2 days, patient symptoms improved drastically following PTCA.

DISCUSSION:

Patients with high degree AV block complicated by MI had more incidence of recurrent high degree AV block or sudden death in the first year of life^[9] CHB in the setting of acute myocardial infarction had higher incidence of decreased LV function and anterior wall MI had higher 30 day mortality to the tune of 60 % as compared to inferior wall MI with 10 to

25%.^[10] According to 2013 ACC AHA guidelines for management of acute myocardial infarction Temporary pacing is indicated for symptomatic bradyarrhythmias unresponsive to medical treatment. (Class I Level of Evidence: C)^[11] According to 2012 ACCF/AHA/HRS update of 2008 ACCF/AHA/HRS guidelines after acute myocardial infarction transient advanced second or third degree infranodal AV block and associated bundle-branch block is an indication for permanent ventricular pacing. Resolution of complete heart block after revascularization has been reported in cases of right coronary artery occlusion^[12] and anomalous dual LAD occlusion^[13]

Sinus bradycardia is the most common complication of inferior wall MI occurring in upto 20% cases attributed to increase in vagal tone in the first 24 hrs also because of sinus nodal or atrial ischemia. AV block may occur secondary to increase susceptibility on AV node to acetylcholine. RCA also supplies AV node by AV nodal artery. LAD artery is known to supply below the AV node and its occlusion should be suspected when broad complexes are associated with heart block^[14]

On reviewing of literature instances of CHB were found after blockage of first septal branch of LAD during angioplasty^[2-5]. Our case displayed how opening blocked LAD can prevent insertion of permanent pacemaker.

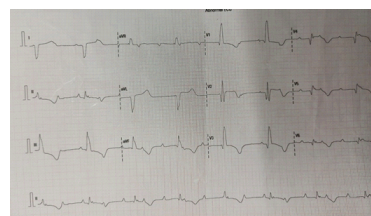


Figure 1 ECG on admission showing complete heart block

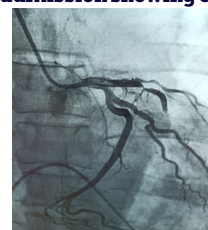

Figure 2 Angiography showing LAD 99% critical stenosis

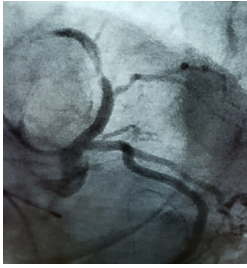


Figure 3: LAO caudal view showing 99% critical LAD lesion

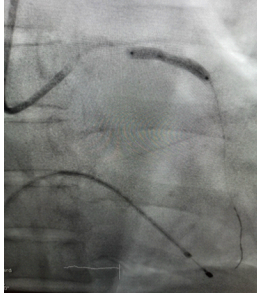


Figure 4: Stent deployment in critical LAD lesion

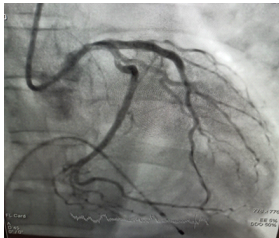

Figure 5: Post PTCA TIMI III flow in LAD

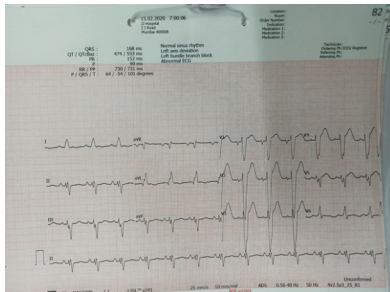


Figure 6: Post angioplasty ECG showing resolution of complete heart block

REFERENCES:

1. Dubois C, Pierard LA, Smeets JP, et al. Long-term prognostic significance of atrioventricular block in inferior acute myocardial infarction. *Eur Heart J* 1989;10:816-20
2. Nee LM, Guttormsen B, Gimelli G. Delayed complete heart block secondary to jailed first septal perforator. *J Invasive Cardiol.* 2007;19(11):E338-339.
3. Kireyev D, Page B, Young HG. Septal infarction and complete heart block following percutaneous coronary intervention of the left anterior descending coronary artery. *J Invasive Cardiol.* 2009;21(3):E48-50.
4. Pillai RV, Daniel R, Joseph DJ. Complete heart block following occlusion of the first septal perforator after coronary stenting. *Indian Heart J.* 2005;57(6):728-730.
5. Irreversible delayed complete heart block secondary to jailed first septal perforator following PCI of the left anterior descending coronary artery. *J Invasive Cardiol.* 2012 Jan;24(1):E13-5. Sadiq MA1, Azman W, Abidin IZ.
6. D. Harpaz, S. Behar, S. Gottlieb, et al. Complete atrioventricular block complicating acute myocardial infarction in the thrombolytic era. *SPRINT Study Group and the Israeli Thrombolytic Survey Group. Secondary Prevention Reinfarction Israeli Nifedipine Trial J Am Coll Cardiol*, 34 (1999), pp. 1721-1728
7. P. Harikrishnan, T. Gupta, C. Palaniswamy, et al. Complete heart block complicating ST-segment elevation myocardial infarction: temporal trends and association with in-hospital outcomes *J Am Coll Cardiol EP*, 1 (2015), pp. 529-538
8. R.J. Goldberg, J.C. Zevallos, J. Yarzebski, et al. Prognosis of acute myocardial infarction complicated by complete heart block (the Worcester Heart Attack Study) *Am J Cardiol*, 69 (1992), pp. 1135-1141
9. The clinical significance of bundle branch block complicating acute

10. myocardial infarction. 2. Indications for temporary and permanent pacemaker insertion. Hindman MC, Wagner GS, JaRo M, et al. *Circulation.* 1978;58:689-699.
11. Prognostic importance of complete atrioventricular block complicating acute myocardial infarction. Aplin M, Engstrom T, Vejstrup NG, Clemmensen P, Torp-Pedersen C, Køber L, TRACE Study Group. *Am J Cardiol.* 2003 Oct 1; 92(7):853-6.
12. 2013 ACCF/AHA guideline for the management of ST-elevation myocardial infarction: a report of the American College of Cardiology Foundation/American Heart Association Task Force on Practice Guidelines. O' Gara PT, Kushner FG, Ascheim DD, et al. *Circulation.* 2012;127:0.
13. *Am Heart J.* 1988 Jan;115(1 Pt 1):179-81. Resolution of complete heart block after right coronary artery angioplasty. Moreyra AE1, Horvitz L, Present SB, Kostis JB
14. Successful restoration of complete heart block to normal sinus rhythm by primary angioplasty of dual left anterior descending artery. Sinha SK, Mishra V, Jha MJ, et al. *Cardiol Res.* 2017;8:73-76.
15. Percutaneous coronary intervention for persistent complete heart block complicating inferior myocardial infarction. Ramamurthy S, Anandaraja S, Matthew NJ *Invasive Cardiol.* 2007 Dec; 19(12):E372-4.