



ORIGINAL RESEARCH PAPER

Ayurveda

MANAGEMENT OF MASHAKA (MOLE) BY AGNIKARMA – A CASE REPORT.

KEY WORDS: Ayurveda, Agnikarma, Mashaka, Mole.

Bijendra Shah*	Teaching Assistant Department Of Shalya Tantra, Ayurveda Campus & Teaching Hospital, IOM, TU, Kathmandu, Nepal *Corresponding Author
Raj Kishor Sah	Associate Prof. and HOD Department Of Shalya Tantra, Ayurveda Campus & Teaching Hospital, IOM, TU, Kathmandu, Nepal
Rupesh Sonam	Ayurveda Physician, Department Of Shalya Tantra, Ayurveda Campus & Teaching Hospital, IOM, TU, Kathmandu, Nepal

ABSTRACT Ayurveda is a science where a medical and surgical procedure are described a years back. *Agnikarma* is the one of minor surgical procedure in Ayurveda which is done by the application of *Agni*, heat. *Masaka* is painless, hard black eruption on the skin. It can be compared with mole in modern science. In the case patient of 24 years male came with complain of mass in forehead. Mass was diagnosed with *mashaka* (mole) on clinical basis. *Agnikarma* was done for the mass. After 2 week lesion was healed up with no any complain of bleeding, infection of wound, pain and scar. Since there is no chance of reoccurrence, *Agni karma* is the best methods of the treatment of *Mashaka* (mole).

INTRODUCTION

Agnikarma is the procedure where there the disease is treated by the application of heat. There is no chance of reoccurrence of disease which is treated with *Agnikarma* and it cures the disease which are not treated with medicine, surgery and Kshar Karma.^[1] There is different *kramas* is Ayurveda but among them *agnikarma* is called as best karma for the treatment of disease. It is described in various Samhita in Ayurveda and can be done for various disease.^[2]

Among *Ksudra roga Mashaka* is one. In *Sushruta Mashaka* is described as hard, painless, black and elevated eruption on the body (skin) resembling the *masha* pulse in shape, caused by the aggravation of *vayu*.^[3] Similarly, according to *vagvata* black, painless, sprouts on the skin, resembling *tila* (sesame seed) are known as *tilakalaka*. Those only are elevated known as *mashaka* when they are raised.^[4] *Mashaka* can be compared with mole in modern science.

Mole are common type of skin growth often appears as small, dark brown spots and are caused by cluster of pigmented cells (melanocytes). The medical term for the moles is *nevi*.^[5] *Naevus* means a lesion which is present since birth. Although many of these may be present since birth, yet other appears appear later in life.^[6] Melanocytes migrate from the neural crest to the basal epidermis during embryogenesis. When Melanocytes aggregates in the dermis or at the dermo-epidermal junction, they are called *naevus* cells.^[7]

Among the treatment of *mashaka Agni* is one indicated both in *Asthanga Hridaya* and *Sushruta*.^{[8][9]}

A CASE REPORTS

A 24 years boy came in Ayurveda Campus teaching hospital with complain of mass in forehead since birth. It was gradually increasing in size and associated with itching. There was no history of swelling, fever, pain. There was no any aggravating and elevating factors. Patient was not gone for any medical intervention for the mass. Patient was not diabetic, hypertensive and no history of any chronic disease. There was no history of carcinoma in the family.

On examination mass was non tender, soft in consistency, immovable, regular margin, was of about 0.5 mm in size and black in color. [Fig. 1]

On the basis of clinical examination it was diagnosed as *Mashaka* (mole).

MATERIAL AND METHODS

Material required: *Panchadhatu shalaka*, *haridra churna*, *aloevera*, *trifala kasaya*, Gas stove,

TREATMENT PLAN:

Agnikarma was planned for the patient.

INVESTIGATION: CBC, ESR, HIV I/II, HBsAg, HCV

METHODS:

First of all patient was kept in sitting position. Painting was done. *Panchadhatu shalaka* was heated on the stove. After *shalaka* got red hot it was applied on the mass. *Aloevera* was applied immediately after it. It was repeated up to *smakyak laksan* seen. After the procedure *haridra* powder was applied on the lesion and left it opened. Patient was advised not to wet the lesion till 24 hour.

RESULTS AND DISCUSSION:

Agnikarma is the process in which heat is used so it is specially done in the *vataj kaphaj byadhi* as it has action of *Ushna*, *Tikshna*, *Sukshma*, *Vyavayi*, *Vikasi* and *Pachana*. In *Mashaka vataj dosha* is *viatiated* so *agnikarma* is applicable in it. As per Dr. Ven Haff said, metabolism of local tissue is improved in the tissue where the head burns.^[10] It gives additional heat to the *dhatwagni* and removes the *shrotabarodh*. So there is less chance of recurrence as well. Activation of *dhatwagni* will improve metabolism and circulation will heals in new tissue formation and there is less chance of scar formation.

In the case, Complain of the patient was completely resolved and the lesion was also healed up within 2 week. [Fig 2]

CONCLUSION:

With this case it can be concluded that *Agnikarma* can be done for the *Mashaka* a mole. It is effective procedure. There is no need of anesthesia. There is no chance of bleeding and reoccurrence as well. In the case, as there is no any scar left, it can be developed for cosmetic purposes also.

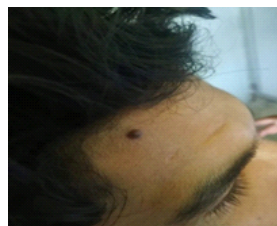

Fig-1: Before Treatment

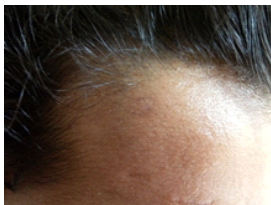


Fig-2: After treatment

REFERENCES

1. Dr. Anant Ram Sharma, Sushrut Samhita of Maharsi Sushrut vol I, Sutrasthana 12/3, Chaukhamba Surbharati Prakasan, Vanarasi: 2017. Pp 85
2. Jadhav DK, Jangid S. Agnikarma in ayurved": an overview. International Journal of Science & Healthcare Research. 2018;3(1):39-44.
3. Dr. Anant Ram Sharma, Sushrut Samhita of Maharsi Sushrut vol II chikitsasthana 20/23, Chaukhamba Surbharati Prakasan, Vanarasi: 2017. Pp 331
4. Prof. K.R. Shrikanta Murthy, Vagbhata's Astanga Hridayam, English Translation Vol III Uttarstyana 31/25b-25a, Chowkhamba Krishnadasa Academy, Vanarasi, 6th Edition 2012 (reprint), Pp 295
5. <https://www.mayoclinic.org/diseases-conditions/moles/symptoms-causes/syc-20375200>
6. Somen Das, A manual on clinical Surgery, Examination of lump or swelling, Dr. S.Das, Calcutta. 4th edition 2006, Pp-122
7. Bailey and love, Bailey and love's Short practice of surgery, Skin and subcutaneous tissue, CRC Press Taylor and Francis Group, 2018. Pp599