



ORIGINAL RESEARCH PAPER

Dental Science

UNICYSTIC MURAL AMELOBLASTOMA. A CASE REPORT AND REVIEW OF CLINICOPATHOLOGIC FEATURES

KEY WORDS:

Dr Jasbir Kaur	M.D.S Prof & Head Department Of Dentistry Guru Gobind Singh Medical College & Hospital Faridkot-151203
Dr Rohit Chopra	M.D.S Associate Professor Department Of Dentistry Guru Gobind Singh Medical College & Hospital Faridkot-151203
Dr Anantpreet Singh*	M.D.S Assistant Professor Department Of Dentistry Guru Gobind Singh Medical College & Hospital Faridkot-151203 *Corresponding Author

ABSTRACT

Unicycstic ameloblastoma refers to those cystic lesions that show clinical, radiological or gross features of a jaw cyst but on histological examination a typical unicycstic ameloblastoma have epithelium lining cyst with or without luminal and or mural tumor proliferation. Unicycstic ameloblastoma is a less encountered variant of the ameloblastoma and is believed to be less aggressive. This case report presents a case of unicycstic ameloblastoma that involved the right posterior mandible of a 35-year-old male, and with no reported recurrence after one year follow-up.

INTRODUCTION

Ameloblastoma is the most common tumor of odontogenic origin which develops from epithelial cellular elements and dental tissues in their various phases of development.¹ Ameloblastoma is also known as solid or multicystic ameloblastoma and is relatively rare odontogenic epithelial neoplasm that has traditionally been characterized as persistent and aggressive in nature. These locally invasive benign lesions usually originate in the mandibular molar-ramus area.² Very little is known regarding the etiology of ameloblastoma.³ Ameloblastoma generally presents as a slowly enlarging asymptomatic facial swelling.⁴ However, the tumor may cause symptoms such as pain, malocclusion, the loosening of teeth or ulceration.² Histopathologically ameloblastoma has been classified into several subtypes including follicular, cystic, acanthomatous, plexiform, basal cell and granular cell. It occurs in all age groups and the peak incidence is in the 3rd and 4th decades.² Of all the ameloblastomas more than 80% are solid or multicystic variants, and the remaining 20% is shared with unicycstic ameloblastoma and peripheral ameloblastoma.¹ Unicycstic Ameloblastoma (UA) was first described by Ackermann et al. in 1988.⁵ The unicycstic ameloblastoma refers to those cystic lesions that show clinical and radiographic characteristics of an odontogenic cyst but histologically show a typical ameloblastomatous epithelium lining, with or without luminal and/or mural tumor proliferation.⁶ This paper illustrates a case of unicycstic ameloblastoma of the mandible in an 35 years old male.

CASE REPORT

A 35 years old male was referred to the Department of Dentistry in G.G.S Medical College & Hospital, Faridkot with chief complaint of swelling in lower right posterior region of face since 1 year. Swelling was gradual in onset and slowly increased to present size with no history of paresthesia or surface changes. Patient also complained of pain in the same region. Pain was of dull, intermittent in nature and it aggravated on mastication and relieved on rest.

Extra-oral examination (Figure 1) revealed a slight swelling measuring of 1X2 cm in the mandibular right posterior region. The margins were not clearly distinct and skin over the swelling appeared normal, with no visible pulsation, surface changes or discharge. On palpation, swelling was non-tender, firm in consistency; no local rise of temperature was felt. Submandibular lymph nodes were non-palpable.

Intraoral examination revealed slight expansion of buccal

cortical plate and a solitary oval swelling of 2x2cm along with expansion on lingual aspect of 45 and 46. On palpation, egg shell crackling was felt in lingual plate in 46 region along with grade I mobility of 45, 46. Neither discharge nor pulsation was seen. Right premolars and molars were non-carious. On needle aspiration, thick yellowish fluid was aspirated.

Orthopantomograph revealed a well defined unilocular radiolucency extending from lower right first premolar to first molar with resorption of mesial root of first molar and second premolar (**Figure 2**). There was no displacement of roots in lower right posterior region. Routine blood investigations like complete blood count were done, which were normal. Based on patient's history, clinical finding and radiological findings, the lesions included in differential diagnosis were odontogenic keratocyst, dentigerous cyst and ameloblastoma.

Enucleation (**Figure 3a**) along with extraction of 44, 45 and 46 was done under local anaesthesia and tissue specimen (**Figure 3b**) was sent for histopathological examination. Microscopically, section showed a cystic lesion with lining of palisaded columnar cells with foci of keratinization. Also nests of ameloblastomatous epithelium within the wall were seen. Sections examined show an occasional island of tumor cells exhibiting peripheral palisading. The individual tumor cells are basaloid, have hyperchromatic nuclei and scant amount of cytoplasm. The occasional tumor island shows presence of stellate reticulum in the center. The background shows fibrocollagenous stroma (**Figure 4,5**). Overall features were suggestive of unicycstic ameloblastoma-mural type.

DISCUSSION

Ameloblastoma is a benign, locally invasive odontogenic neoplasm with variable clinical expression. It accounts for 1% of all cysts/tumors of jaws and 18% of all odontogenic neoplasms. It is typically slow growing, and rarely metastasizes but has a high recurrence rate (55-90%) (if not removed adequately). As per the WHO system of 2003, ameloblastoma is classified based on differences in biologic behavior, treatment plan and recurrence rate as follows:

- (1) Classic solid/multicystic ameloblastoma
- (2) Unicycstic ameloblastoma
- (3) Peripheral ameloblastoma
- (4) Desmoplastic ameloblastoma, including the so-called hybrid lesions.⁷

The gender distribution shows a slight male predilection with a male to female ratio of 1.6 : 1.⁸ However, it is known that the mean age is approximately 25.3 years for unicycstic amelob

lastoma and it peaks in the second and third decades.⁹In the present case, the patient was 35 years old male.

More than 90% are found in the mandible, usually in the posterior region followed by the parasymphysis region, the anterior maxilla and the posterior maxilla.¹⁰The site in our case was mandibular posterior region (body region).

The radiographic appearance of UCAs has been divided into 2 main patterns: unilocular and multilocular, the unilocular pattern being more common. Among the unilocular lesions, dentigerous variant is more common than non-dentigerous one.^{11,12} Eversole et al. identified predominant radiographical patterns for Unicystic ameloblastoma: unilocular, scalloped, macromultilocular, pericoronal, interradicular, or periapical expansile radiolucencies.¹³The lesion in the present case was a non-dentigerous, variant of unicystic ameloblastoma.

In a clinicopathologic study of 57 cases of unicystic ameloblastoma, Ackermann classified this entity into the following three histologic groups:

GROUP I—

luminal UA (tumor confined to the luminal surface of the cyst);

GROUP II—

intraluminal/plexiform UA (nodular proliferation into the lumen without infiltration of tumor cells into the connective tissue wall);

GROUP III—

mural UA (invasive islands of ameloblastomatous epithelium in the connective tissue wall not involving the entire epithelium). According to this classification, our case study belongs to Group III.¹⁴ According to this classification the lesion in our case falls in Group III.

As general protocol for treatment planning of any lesion with impression of cyst, or unicystic ameloblastoma on radiograph, incisional biopsy should be considered. However Ackerman *et al.* and Isacson and associates¹⁵ recommend not to perform such incisional biopsy as it does not always lead to confirmatory diagnosis and hence they suggested that entire tissue must be included.

The treatment of ameloblastoma ranges from a conservative approach to radical resection. Available treatment options include enucleation followed by use of Carnoy's solution; marsupialization followed by enucleation; marginal resection and aggressive resection.¹⁶ However, it is difficult to determine the most appropriate form of treatment for these lesions. It is still more controversial in case of unicystic ameloblastoma.^{17,18,19}

Marx and Stern^{20,21} have advocated that treatment approach should be based upon the histopathological examination of ameloblastomas. According to their recommended treatment options, only transmural microinvasive and invasive subtypes require surgical resection whereas ameloblastoma in situ and intramural microinvasive subtypes should be treated with enucleation.

In the present case, there were seen occasional islands of tumor cells in fibrocollagenous stromal background. The final diagnosis was established as unicystic ameloblastoma with mural proliferation and microinvasive subtypes, According to Marx and Stern, treatment planned in our case is enucleation and followed-up for one year with no signs of recurrence.

CONCLUSION

All unicystic and unilocular radiolucent lesion in the posterior region of orthopantomograph should never be thought of a cyst for sure. Moreover, on aspiration if cystic fluid comes from such lesions, one must consider mural type of unicystic ameloblastoma as differential diagnosis in addition to cyst.

Final diagnosis has to be made histopathologically. Moreover, whatever surgical approach the surgeon decides to take, long term follow up is mandatory as recurrence of unicystic ameloblastoma may be long delayed.

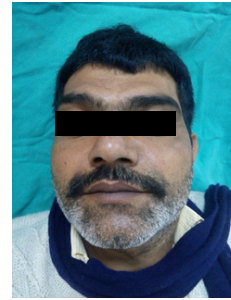

FIGURE 1: EXTRA-ORAL VIEW SHOWING FACIAL ASSYMMETRY

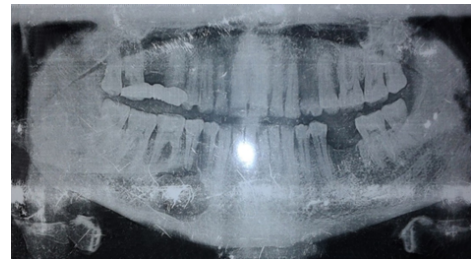

FIGURE 2: ORTHOPANTOMOGRAPH SHOWING UNICYSTIC LESION

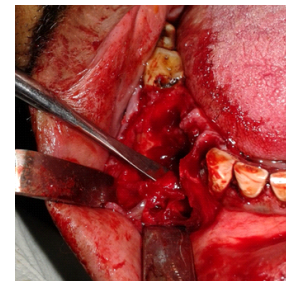

FIGURE 3a: INTRAOPERATIVE PHOTOGRAPH SHOWING ENUCLEATION.

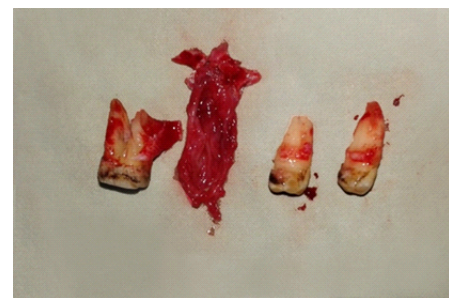


FIGURE 3b: SHOWING CYSTIC LINING AND EXTRACTED TOOTH

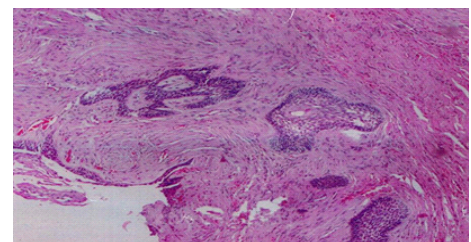


FIGURE 4: HISTOPATHOLOGICAL PHOTOMICROGRAPH SHOWING ISLANDS OF TUMOR CELLS

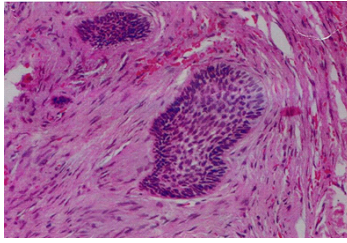


FIGURE 5: HISTOPATHOLOGICAL PHOTOM ICRO MICROGRAPH SHOWING INDIVIDUAL BASALOID TUMOR CELLS HAVING HYPERCHROMATIC NUCLEI AND SCANT AMOUNT OF CYTOPLASM

REFERENCES

1. H. P. Philipsen and P. A. Reichart, "Unicystic ameloblastoma. A review of 193 cases from the literature," *Oral Oncology*, vol. 34, no. 5, pp. 317–325, 1998.
2. Huang IY, Lai ST, Chen CH, Chen CM, Wu CW, Shen YH. Surgical management of ameloblastoma in children. *Oral Surg Oral Med Oral Pathol Oral Radiol Endod* 2007;104:478-85.
3. Daramola JO, Ajagbe HA, Oluwasanmi JO. Ameloblastoma of the jaws in Nigerian children: A review of sixteen cases. *Oral Surg Oral Med Oral Pathol* 1975;40:458-63.
4. Al-Khateeb T, Ababneh KT. Ameloblastoma in young Jordanians: A review of the clinicopathologic features and treatment of 10 cases. *J Oral Maxillofac Surg* 2003;61:13-8.
5. G. L. Ackermann, M. Altini, and M. Shear, "The unicystic ameloblastoma: a clinicopathological study of 57 cases," *Journal of Oral Pathology*, vol. 17, no. 9-10, pp. 541–546, 1988.
6. T. J. Li, Y. T. Wu, S. F. Yu, and G. Y. Yu, "Unicystic ameloblastoma: a clinicopathologic study of 33 Chinese patients," *American Journal of Surgical Pathology*, vol. 24, no. 10, pp. 1385–1392, 2000.
7. P. A. Reichart and H. P. Philipsen, *Odontogenic Tumors and Allied Lesions*, Quintessence, Hanover, Germany, 2004.
8. Nagalaxmi V, Sangmesh M, Kotya NM, Kodangal S, Chappidi V and Goyal S. Unicystic Mural Ameloblastoma: An Unusual Case Report. *Hindawi case reports in dentistry* 2013;957418: 1-6.
9. Burcu S, Emre B, Tulin O, Akin O. Recurrent unicystic mural type ameloblastoma in a 9 year old boy, 8 years follow up. *Contemporary Clinical Dentistry* 2013;4(4):569-572.
10. K. R. K. Kumar, G. B. George, S. Padiyath, and S. Rupak, "Mural unicystic ameloblastoma crossing the midline: a rare case report," *International Journal of Odontostomatology*, vol. 6, no. 1, pp. 97–103, 2012.
11. L. R. Eversole, A. S. Leider, and D. Strub, "Radiographic characteristics of cystogenic ameloblastoma," *Oral Surgery Oral Medicine and Oral Pathology*, vol. 57, no. 5, pp. 572–577, 1984.
12. A. Peter, P. A. Reichart, and H. P. Philipsen, "Unicystic ameloblastoma," in *Odontogenic Tumors and Allied Lesions*, pp. 77– 86, Quintessence, London, UK, 2004, editorial and consensus conference held in Lyon, France (WHO,IARD) in July 2003 in conjunction with preparation of new WHO Blue Book, Path-ology and genetics of tumors of head and neck.
13. Kumar KR, George B, Padiyath S and Rupak S. Mural unicystic ameloblastoma crossing the midline: a rare case report. *Int J Odontostomat* 2012;6(1):97-103.
14. Ackermann GL, Altini M, Shear M. The unicystic ameloblastoma: A clinicopathological study of 57 cases. *J Oral Pathol* 1988; 17: 541-6.
15. Isacsson G, Andersson L, Forsslund H, Bodin I, Thomsson M. Diagnosis and treatment of the unicystic ameloblastoma. *Int J Oral Maxillofac Surg* 1986;15:759-64.
16. Ueno S, Mushimoto K, Shirasu R. Prognostic evaluation of ameloblastoma based on histologic and radiographic typing. *J Oral Maxillofac Surg* 1989;47:11-5.
17. R. Scariot, R. V. da Silva, W. da Silva Felix Jr., D. J. da Costa, and N. L. B. Rebellato, "Conservative treatment of ameloblastoma in child: a case report," *Stomatologija*, vol. 14, no. 1, pp. 33–36, 2012.
18. T. Hasegawa, Y. Imai, D. Takeda et al., "Retrospective study of ameloblastoma: the possibility of conservative treatment," *Kobe Journal of Medical Sciences*, vol. 59, no. 4, pp. E112–E121, 2013.
19. S. R. Naidu, R. J. Hegde, V. N. Devrukhkar, and A. R. Patel, "Conservative management of unicystic ameloblastoma in a young child: a case report," *Journal of Indian Society of Pedodontics and Preventive Dentistry*, vol. 32, no. 3, pp. 251–254, 2014.
20. R. E. Marx and D. Stern, "Odontogenic tumors: hamartomas and neoplasms," in *Oral and Maxillofacial Pathology: A Rationale for Diagnosis and Treatment*, pp. 671–678, Quintessence, 2012.
21. Garcia N, Oliveira D, Rodrigues M. Unicystic Ameloblastoma with Mural Proliferation Managed by Conservative Treatment. *Case Reports in Pathology*. 2016;2016:1-4.