



ORIGINAL RESEARCH PAPER

Gynaecology

TO STUDY THE SENSITIVITY AND SPECIFICITY OF TRANSVAGINAL SONOGRAPHY AS COMPARED TO HYSTEROSCOPY IN PATIENTS OF ABNORMAL UTERINE BLEEDING

KEY WORDS: Abnormal Uterine Bleeding , Hysteroscopy , Transvaginal Sonography ,less Invasive ,cost Effective

Dr Rosy Karan

Junior Resident ,Dept Of Obsterics And Gynaecology ,AFMC Pune

Dr (Brig) Shakti Vardhan

Cosultant & HOD, Dept Of Obsterics And Gynaecology, AFMC Pune

ABSTRACT

Abnormal Uterine Bleeding is a common symptom in perimenopausal age group ,often requiring OPD visit. Eventhough the hysteroscopy holds the gold standard investigation ,being invasive ,costly and more skillful makes it a second choice amongst gynaecologist ,TVS can be useful in OPD settings for evaluation prior to any invasive investigation ,in our study we found that in perimenopausal women the investigation was significantly effective in evaluating AUB .

INTRODUCTION

Abnormal uterine bleeding (AUB) is one of the most common reasons for women seeking gynaecological advice. More than 40% of affected women with AUB are reported to have intrauterine abnormalities (1). In the sexually active age group mainly , 70% of all gynecological outpatient visits are for abnormal uterine bleeding .(6)

The diagnosis and evaluation of abnormal uterine bleeding is to find the cause of bleeding , which can be classified as per the PALM-COEIN (Polyp, Adenomyosis, Leiomyoma, Malignancy, Endometrial hyperplasia, Bleeding disorder ,Ovulatory disorders, Endometrial, Iatrogenic and Not otherwise classified) classification system.(7) .

The most common anatomical causes of AUB in women are submucosal fibroids, endometrial polyps , and sometimes Endometrial Hyperplasia .Transvaginal ultrasound (TVS) has been found as a safe, non- invasive and simple to perform procedure that provides help to prioritise patients who need further evaluation; however, many concerns have been raised about its accuracy (4,5,9,10).

According to the safety guidelines of the British Medical Ultrasound Society (BMUS), it is a recommended fact while performing TVS if the Thermal Index (TI) is between 2.5 and 3.0, the scan time should be less than 1 minute (12) .Also the potential risk of getting infection via the transvaginal probe should be addressed (13) Endometrial polyps are benign localized outgrowths of the endometrium that contain glands and stroma (13,14) , The prevalence of endometrial polyps is thought to be higher in infertile women (15). In a prospective study of 1000 patients who had undergone hysteroscopic evaluation of the uterine cavity before in vitro fertilization (IVF), the prevalence of endometrial polyps was found to be 32% (16,17). While this may suggest a causal association between polyps and infertility, Age, hypertension, obesity, along with diabetes are well established risk factors for the development of endometrial polyps (19,20). Of these risk factors, age is perhaps the most well-known risk factor .There also appears to be an association between endometrial polyps and other benign gynecologic conditions like cervical polyps and endometriosis (21).

Women using tamoxifen are also known to have a higher risk of developing endometrial polyps, The risk of malignancy increases with age , polyp size and concomitant use of tamoxifen (22).An endometrial polyp on sonography appears as a hyperechoic endometrial mass with regular contours inside the uterine cavity either partially or fully occupying space therein . Occasionally, cystic spaces may appear within the polyp (23) Performing sonography in the proliferative phase of the menstrual cycle often provides the most reliable

results (24)

Hysteroscopy along with guided biopsy is advocated as the gold standard for diagnosing endometrial polyps.(15) Hysteroscopy also helps in assessment of size, number, and vascular characteristics of endometrial polyps . Before the routine use of hysteroscopy, blind dilation and curettage were used for the diagnosis of endometrial polyps .This technique, however, caused polyp fragmentation making histopathologic diagnosis difficult (14). The low sensitivity of 8% to 46% and NPV of 7% to 58% of this blind endometrial sampling when compared to hysteroscopy with guided biopsy was suggestive that the former technique lacks in diagnosing endometrial polyps significantly (16,17)Hysteroscopy compared to TVS has proven diagnostic value in evaluation of most of the intrauterine pathologies, is costly and needs specific equipment and in some patients, anesthesia may be required (10,11). Our study was aimed at premenopausal women with Abnormal Uterine Bleeding where the TVS was used prior to Hysteroscopy as its equally informative and less invasive , cheaper , safer and fast .

Materials And Method :

SOURCE OF DATA :

all eligible cases reporting with AUB in Gynae OPD during the period of study

STUDY DESIGN – Diagnostic evaluation study

PLACE OF STUDY- Armed Forces Medical College , Pune

DURATION OF STUDY – from 2018-2019

SAMPLE SIZE – 144.

INCLUSION CRITERIA

All premenopausal women with abnormal uterine bleeding ,With informed and valid consent ,144 patients , willing to participate in study

EXCLUSION CRITERIA

Post menopausal women , All pregnant women

TRANSVAGINAL ULTRASONOGRAPHY .

Transvaginal sonography (TVS) was used as an initial investigation , was performed in the follicular phase of the menstrual cycle (days 5-13) after stopping of bleeding and before diagnostic hysteroscopy by a standard 2D Ultrasonography machine with a transvaginal 6 MHz probe . TVS and hysteroscopy were both planned to be performed in the same cycle. Uterine cavity abnormalities comprising polyp lesions, uterine fibroids, uterine congenital anomalies

like septum, adhesion and endometrial hyperplasia are investigated.

HYSTEROSCOPY

Hysteroscopy was done using a 3 mm hysteroscope with standard light source, in office with required

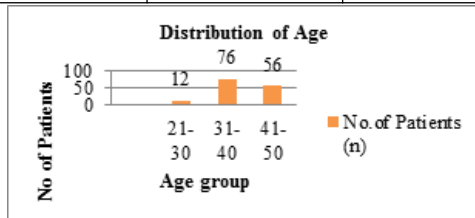
Table -1

TVS test	Hysteroscopy		Total
	Abnormal hysteroscopy	Normal hysteroscopy	
Abnormal TVS	72	3	75
Normal TVS	12	57	69
Total	84	60	144

anaesthetic measures. If there was any intrauterine pathology, details of the same were noted. As a part of the procedure at the end, the hysteroscope was slowly withdrawn through the cervical canal to visualize and note any intra-cervical pathology. Parameters studied were the presence of endometrial hyperplasia, sub-mucosal fibroid or an endometrial polyp. The relevant data was stored for analysis. The study was carried out from 2018 to 2019. A total of 144 patients consented and were enrolled for the study. The age distribution of the patients is as follows (Table 1 & 2).

Table -2

Age group	No. Of Patients (n)	Percent (%)
21-30	12	8.4
31-40	76	52.72
41-50	56	38.88
Total	144	100.0



Out of 144, in age group 31- 40 and 41-50 maximum 76 (52.72%) and 56 (38.8 %) patients have abnormal uterine bleeding (AUB) respectively. Mean age of patient was 40.07 ± 5.73. AUB was most common in the 31-40 yrs age group (52.72%) age groups, followed by age group between 41-50 yrs (38.8%). Both procedures were performed in 144 patients with abnormal uterine bleeding, Office hysteroscopy was performed on patients with AUB after undergoing TVS and it was observed that no of patients 12 (as per table no 3) with normal finding on TVS were having conclusive disorders while some of them were not having any disorder as perceived by the TVS As can be seen in the following correlation between hysteroscopy and TVS in Table -3

Table -3

TVS test	Hysteroscopy		Total
	Abnormal hysteroscopy	Normal hysteroscopy	
Abnormal TVS	72	3	75
Normal TVS	12	57	69
Total	84	60	144

The results of our study were analyzed statistically.

Sensitivity, specificity, disease prevalence, positive predictive value and negative predictive value were calculated online by using medical (Table - 4)

Table -4

Statistical index	Value	95% CI
Sensitivity	85.71%	76.38% to 92.39%

Specificity	95.00%	86.08% to 98.96%
Positive Predictive Value	96.00%	88.81% to 98.64%
Negative Predictive Value	82.61%	73.71% to 88.95%
Accuracy	89.58%	83.40% to 94.05%

kappa was 31.57, P value by the chi square test (P value= 0.0001) less than 0.05, Association between TVS and hysteroscopy were statistically significant. Hysteroscopy is more efficient than TVS for AUB as can be seen in Table 5

Table-5 Association between TVS and Hysteroscopy

Correlation	Number (n= 144)
Normal TVS & Normal Hysteroscopy	57
Normal TVS & Abnormal Hysteroscopy	12
Abnormal TVS & Normal Hysteroscopy	3
Abnormal TVS & Abnormal Hysteroscopy	72

FALSE POSITIVES

There was disagreement noticed between two procedures for few lesions. Two uterine cavities, where TVS shows abnormal findings were having normal Hysteroscopy

FALSE NEGATIVES

There were 12 cases (as per Table no 3) when the lesion in uterine cavity was missed by TVS and were reported as normal finding and while evaluation with hysteroscopy were detected with abnormal findings

CONCLUSIONS

Our study was aimed establishing the sensitivity, specificity of TVS Vs Hysteroscopy as modality of diagnosis in evaluation of causes of abnormal uterine bleeding patients in premenopausal group.

Our study included 144 patients with these complains and the conclusion drawn was that on hysteroscopy we had 41.66 % of normal uterine cavity, and rest 58.33 % had a conclusive uterine disorder during the same, while at the same time TVS had 47.91% normal uterine cavity and 52.09% had conclusive uterine anomaly. TVS compared hysteroscopy had 85.71% sensitivity and 95% specificity with positive predictive value of 96% and Negative predictive value 86.21 % (table no 2).

AUB is a creator of dilemma for gynecologist. The appropriate tool to establish the diagnosis in a clinching way should be accurate, cost effective, easy to do, safe, non-invasive as far as possible, and well tolerated by patient. We have established in our study that TVS has significant sensitivity and specificity as a non invasive tool in evaluating a patient of Abnormal uterine bleeding compared to invasive procedures like Hysteroscopy. In our study the results were comparable enough to recommend TVS as an initial modality of evaluation in abnormal uterine bleeding worth it because of comparable results as obtained by evaluating, we recommend TVS as a valuable tool in the armour of a gynecologist to evaluate abnormal uterine bleeding

REFERENCES:

- Liu Z, Doan QV, Blumenthal P, Dubois RW. A systematic review evaluating health-related quality of life, work impairment, and health-care costs and utilization in abnormal uterine bleeding. *Value in health.* 2007;10(3):183-194.
- Berridge DL, Winter TC. Saline infusion sonohysterography: technique, indications, and imaging findings. *Journal of ultrasound in medicine.* 2004;23(1):97-112.
- Seshadri S, El-Toukhy T, Douiri A, Jayaprakasan K, Khalaf Y. Diagnostic accuracy of saline infusion sonography in the evaluation of uterine cavity abnormalities prior to assisted reproductive techniques: a systematic review and meta-analysis. *Human Reproduction Update.* 2014;21(2):262-274.
- El Tagy AH, Motaal E, Abd AO, Awaly M. Comparison between 3D-Transvaginal Ultrasound and Hysteroscopy in Detecting Uterine Cavity Abnormalities. *The Egyptian Journal of Hospital Medicine (October 2018).* 2018;73(7):7160-7164.
- Ludwin A, Pity ski K, Ludwin I, Banas T, Knafel A. Two-and three-dimensional ultrasonography and sonohysterography versus hysteroscopy with laparoscopy in the differential diagnosis of septate, bicornuate, and arcuate uteri. *Journal of minimally invasive gynecology.* 2013;20(1):90-99.
- Brinton LA, Sakoda LC, Sherman ME, Frederiksen K, Kjaer SK, Graubard BI, et

- al. Relationship of benign gynecologic diseases to subsequent risk of ovarian and uterine tumors. *Cancer Epidemiology and Prevention Biomarkers*. 2005;14(12):2929–2935.
7. Munro MG, Critchley HO, Broder MS, Fraser IS, Disorders FWG on M. FIGO classification system (PALM-COEIN) for causes of abnormal uterine bleeding in nongravid women of reproductive age. *International Journal of Gynecology & Obstetrics*. 2011;113(1):3–13.
 8. Clevenger-Hoeft M, Syrop CH, Stovall DW, Van Voorhis BJ. Sonohysterography in premenopausal women with and without abnormal bleeding. *Obstetrics & Gynecology*. 1999;94(4):516–520.
 9. Amis S, Ruddy M, Kibbler CC, Economides DL, MacLean AB. Assessment of condoms as probe covers for transvaginal sonography. *Journal of clinical ultrasound*. 2000;28(6):295–298.
 10. Khan F, Jamaat S, Al-Jaroudi D. Saline infusion sonohysterography versus hysteroscopy for uterine cavity evaluation. *Annals of Saudi medicine*. 2011;31(4):387–392.
 11. Schwärzler P, Concin H, Bösch H, Berlinger A, Wohlgenannt K, Collins WP, et al. An evaluation of sonohysterography and diagnostic hysteroscopy for the assessment of intrauterine pathology. *Ultrasound in Obstetrics and Gynecology: The Official Journal of the International Society of Ultrasound in Obstetrics and Gynecology*. 1998;11(5):337–342.
 12. Harris GR, Church CC, Dalecki D, Ziskin MC, Bagley JE. Comparison of thermal safety practice guidelines for diagnostic ultrasound exposures. *Ultrasound in medicine & biology*. 2016;42(2):345–357.
 13. Baiocchi G, Mancini N, Pazzaglia M, Giannone L, Burnelli L, Giannone E, et al. Malignancy in endometrial polyps: a 12-year experience. *American journal of obstetrics and gynecology*. 2009;201(5):462–e1.
 14. Dreisler E, Stampe Sorensen S, Ibsen PH, Lose G. Prevalence of endometrial polyps and abnormal uterine bleeding in a Danish population aged 20–74 years. *Ultrasound in Obstetrics and Gynecology: The Official Journal of the International Society of Ultrasound in Obstetrics and Gynecology*. 2009;33(1):102–108.
 15. Afifi K, Anand S, Nallapeta S, Gelbaya TA. Management of endometrial polyps in subfertile women: a systematic review. *European Journal of Obstetrics & Gynecology and Reproductive Biology*. 2010;151(2):117–121.
 16. Sharma S. Polyps: Hysteroscopic Diagnosis and Management. In: *Manual of Fertility Enhancing Hysteroscopy*. Springer; 2018. p. 61–78.
 17. Shokeir TA, Shalan HM, El-Shafei MM. Significance of endometrial polyps detected hysteroscopically in eumenorrhic infertile women. *Journal of Obstetrics and Gynaecology Research*. 2004;30(2):84–89.
 18. Indraccolo U, Di Iorio R, Matteo M, Corona G, Greco P, Indraccolo SR. The pathogenesis of endometrial polyps: a systematic semi-quantitative review. *Eur J Gynaecol Oncol*. 2013;34(1):5–22.
 19. Bianchini F, Kaaks R, Vainio H. Overweight, obesity, and cancer risk. *The lancet oncology*. 2002;3(9):565–574.
 20. Nappi L, Indraccolo U, Sardo ADS, Gentile G, Palombino K, Castaldi MA, et al. Are diabetes, hypertension, and obesity independent risk factors for endometrial polyps? *Journal of Minimally Invasive Gynecology*. 2009;16(2):157–162.
 21. Saccardi C, Cosmi E, Borghero A, Tregnaghi A, Dessole S, Litta P. Comparison between transvaginal sonography, saline contrast sonovaginography and magnetic resonance imaging in the diagnosis of posterior deep infiltrating endometriosis. *Ultrasound in Obstetrics & Gynecology*. 2012;40(4):464–469.
 22. Bernstein L, Deapen D, Cerhan JR, Schwartz SM, Liff J, McGann-Maloney E, et al. Tamoxifen therapy for breast cancer and endometrial cancer risk. *Journal of the National Cancer Institute*. 1999;91(19):1654–1662.
 23. Baldwin MT, Dudiak KM, Gorman B, Marks CA. Focal intracavitary masses recognized with the hyperechoic line sign at endovaginal US and characterized with hysterosonography. *Radiographics*. 1999;19(4):927–935.
 24. Sher G, Herbert C, Maassarani G, Jacobs MH. Assessment of the late proliferative phase endometrium by ultrasonography in patients undergoing in-vitro fertilization and embryo transfer (IVF/ET). *Human Reproduction*. 1991;6(2):232–237.
 25. Niknejadi M, Haghighi H, Ahmadi F, Niknejad F, Chehrazai M, Vosough A, et al. Diagnostic accuracy of transvaginal sonography in the detection of uterine abnormalities in infertile women. *Iranian Journal of Radiology*. 2012;9(3):139.
 26. Yavariabdi A, Bartoli A, Samir C, Artigues M, Canis M. Mapping and characterizing endometrial implants by registering 2D transvaginal ultrasound to 3D pelvic magnetic resonance images. *Computerized Medical Imaging and Graphics*. 2015;45:11–25.
 27. Lindheim SR, Adsuar N, Kushner DM, Pritts EA, Olive DL. Sonohysterography: A Valuable Tool in Evaluating the Female Pelvis. *Obstetrical & gynecological survey*. 2003;58(11):770–784.