



TAKAYASU ARTERITIS AFFLICTED YOUNG FEMALE PRESENTING WITH PSEUDO –HYPOTENSION AND SEPSIS

General Medicine

Yatin Gupta

Junior Resident (Academic), SGT Medical College, Hospital And Research Institute, Budhera (Gurugram)

Anshu Makkar*

Assistant Professor, SGT Medical College, Hospital And Research Institute, Budhera (Gurugram) *Corresponding Author

Sheetal Kaul

Assistant Professor, SGT Medical College, Hospital And Research Institute, Budhera (Gurugram)

ABSTRACT

Takayasu arteritis is an inflammatory and stenotic disease of medium and large sized arteries characterized by a strong predilection for the aortic arch and its branches. We present the case of an 18 years old woman who was referred from dermatology department with the complaints of fever and drug allergy. On routine check up she was found to have fever, peeling and scaling of palmar skin, pedal edema and hypotension and was managed initially for septic shock. Takayasu arteritis was suspected on detailed examination. A thorough cardiovascular examination including blood pressure recording from the lower limb revealed hypertension, feeble upper limb pulses but good volume lower limb pulses. Hence the Initial Hypotension in our patient proved to be Pseudo-hypotension. It is recommended that in such cases additional ankle pressure measurement should also be done to avoid misdiagnosis regarding status of the blood pressure.

KEYWORDS

INTRODUCTION

Takayasu arteritis, 'Pulseless Disease' or Reverse Coarctation of Aorta is an inflammatory and stenotic disease of medium and large sized arteries and is characterized by a strong predilection for the aortic arch and its branches. Vascular lesions in TA may be stenotic (93%), occluded (57%), dilated (16%) or aneurysmal (7%).¹ This is an uncommon disease with an estimated annual incidence rate of 1.2-2.6 cases per million. It is most prevalent in adolescent girls and young women. Although it is more common in Asia but it is neither racially nor geographically restricted.²

TA was first reported from Japan in 1908 and is prevalent in Asian population. It is a disease of young women and the age of onset is usually 25-30 years and male to female ratio is 1:8. This is the commonest cause of reno-vascular hypertension in India.³ The aortic arch is more involved in Japan while involvement of abdominal aorta is more in Indian and Korean patients.⁴ Takayasu arteritis is a rare inflammatory vascular disease affecting the aorta and its branches, with an annual incidence of 0.4 to 1 case per million.^{5,6} Carotid and subclavian involvement is common but only one case report has described a combination of subclavian steal syndrome and syncope in this disease.⁷

TA is a panarteritis with inflammatory mononuclear cell infiltrates and occasionally giant cells. There is marked intimal proliferation, fibrosis, scarring and vascularisation of the media and disruption and degeneration of elastic lamina. Involvement of the major branches of the aorta is much more marked at their origin than distally. There occurs narrowing of the lumen with or without thrombosis. The vasa vasorum are frequently involved. Frequency of Arteriographic abnormalities and potential clinical manifestations of arterial involvement in TA are as shown in Table 1.

Table 1. Frequency of arteriographic abnormalities and potential clinical manifestations of arterial involvement in T.A.

Artery	% of Arteriographic Abnormalities	Potential clinical manifestations
Subclavian	93 %	Arm claudication, Raynaud's phenomenon
Common Carotid	58 %	Visual changes, Syncope, TIA, Stroke
Abdominal Aorta	47 %	Abdominal Pain, Nausea, Vomiting
Renal	38 %	Hypertension, Renal Failure

Geographically, it is endemic in Japan and southeast Asia (India). It is

neither racially nor geographically restricted. This is a systemic disease with common clinical manifestations as described in Table 2.⁸

Table 2. Common Clinical manifestations of TA

Features	Percentage	Features	Percentage
Constitutional symptoms	66 %	Hypertension	43 %
Diminished Pulses	88 %	Aortic Regurgitation	33 %
Bruits	77 %	Renal Artery Stenosis	26 %
Pain in Extremities	69 %	Cardiovascular accidents	18 %
Claudication	48 %	Pulmonary Hypertension	12 %

Diagnosis of TA should be suspected strongly in young women who present with decreased or absent peripheral pulses, discrepancies in blood pressure and/or arterial bruit. TA should be suspected whenever a young female comes with the history of fever, headache and/or arm claudication, they should be investigated for Takayasu arteritis or some similar vessel wall disease of middle to large sized arteries.⁹ The diagnosis is confirmed by characteristic pattern of arteriography which includes irregular vessel walls stenosis, post stenotic dilatation, aneurysm formation, occlusion and evidence of increased collateral circulation. Most important laboratory findings are anemia and marked elevation of erythrocyte sedimentation rate or C- Reactive protein. The gold standard of diagnosis is vascular study by arterial angiography, magnetic resonance angiography and CT angiography resonance. American College of Rheumatology has established classification criteria, as shown in Table 3, according to which 3 out of 6 criteria must be fulfilled for diagnosis of Takayasu arteritis.¹⁰

Table 3. American College of Rheumatology's Criteria for Diagnosis of Takayasu arteritis

Criteria	Features
1	Age under 40 at the time of onset of Disease
2	Claudication of Extremities
3	Decreased Brachial Artery Pulse
4	Blood Pressure difference more than 10 mm Hg between arms
5	Bruit over Subclavian arteries or Aorta
6	Angiogram abnormalities : Occlusion or narrowing in Aorta or its main branches

CASE REPORT

An 18 years old female was referred by the Dermatology department of this institute with the chief complaints of fever and drug allergy

for the last 10 days . Patient had taken treatment from some medical practitioner following which she had developed drug allergy resulting in peeling and scaling of palmar skin and pedal edema.

On examination the patient was found to be moderately built and moderately nourished. Her right radial pulse was absent while her left radial pulse was feeble while other lower limb peripheral pulses were palpable and were of good volume. Her Systolic Blood Pressure was 90 mm Hg and Diastolic Blood Pressure was 52 mm Hg when taken in the right upper limb in supine position. Suspecting TA her ankle blood pressure was taken which, surprisingly, came out to be 152/92 mm Hg. Our patient, in fact, had hypertension and not hypotension. This proved that the initially diagnosed Hypotension was in fact Pseudo-hypotension.

Investigations:

C. B. C. :

Hb	11.4 gm/dl
MCV	33.4fl
TLC	15000/Cmm
Platelets	1.8/cmm
Total Bilirubin	0.6 mg/dl
AST/ALT	37/43 U/L
Total Proteins	6.3 mg/dl
Blood Urea	19 mg/dl
Serum Creatinine	1.0 mg/dl
CRP(Latex)	Positive
ESR	18 mm 1st hr
Mantoux	Negative

Fundus Examination: Normal

Two Dimensional Echocardiogram : Normal study ,LVEF 55-60 %

USG Doppler :Upper limb arteries show -

Right Side

- Right Subclavian and Axillary arteries appear reduced in caliber and show decreased peak systolic velocity.
- Right Brachial artery is normal in caliber
- Right Radial and Ulnar arteries show monophasic waveform which show severe stenosis with reduced peak systolic velocity.

Left side : Normal Triphasic flow seen

To sum up USG Doppler findings ,there was reduced caliber and peak systolic velocity of right upper limb arteries only whereas left upper limb arteries had normal caliber and peak systolic velocity.

MR Angiogram Head and Neck :

- Circle of Wills –Normal
- Subclavian Arteries–Show bilateral circumferential narrowing .

Right Subclavian artery shows significant stenosis which is as high as 50-70 % and is narrowest at its origin and also has a concentric narrowing of 50% near origin of right vertebral artery.

Left Subclavian artery shows a significant stenosis , as high as 70-80 % present just 1.5 cm from its origin from the aortic arch and it is attenuated in caliber and has vessel wall thickening as shown in Fig.1

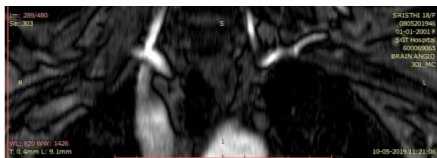


FIG 1 (Left Subclavian artery stenosis)

Vertebral Arteries :

- Right Vertebral artery , adjacent to its origin , shows concentric narrowing of 50 % . Left Vertebral artery,1.5 cm from its origin from arch of aorta , shows significant stenosis of 70-80 % . It appears attenuated with normal wall thickness as shown in Fig. 2

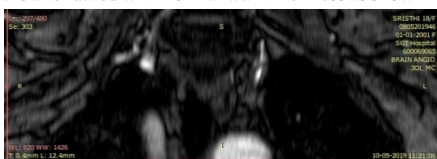


FIG 2 (Right & Left Vertebral artery)

DISCUSSION

Takayasu arteritis is a large vessel vasculitis among young women that mainly affects the aorta and its branches. Pulses are commonly absent or feeble in the involved vessels , particularly involvement of the Subclavian artery . Hypertension occurs in 32-93 % of patients ¹. However ,disease-related subclavian or brachial obstructions can lead to apparent hypotensive brachial blood pressure values. By contrast, arterial hypertension is also frequent in this disease, possibly unrecognized in case of solitary brachial blood pressure measurement. ¹¹

We present the case of an 18 year old woman who came with the chief complaints of fever , drug allergy , suspected sepsis with hypotension. At the time of admission she was found to be hypotensive but on suspicion of Takayasu arteritis , her blood pressure was recorded from her ankle as well and to our surprise, she turned to be hypertensive. On investigation she was also found to have high total leukocyte count , positive C reactive protein, mild anaemia and slightly high ESR .

Her USG Doppler showed reduced caliber and peak systolic velocity of right upper limb arteries whereas left upper limb arteries had normal caliber and peak systolic velocity. Her head and neck M R Angiogram showed concentric narrowing of both the Subclavian Arteries. The patient fulfilled four of the six ACR criteria (American College of Rheumatology criteria) for Takayasu arteritis .

As stated above, hypertension is frequent in this disease .Nevertheless ,when the subclavian arteries are affected , brachial measurement of arterial pressure alone is ineffective because a falsely normal or decreased blood pressure might be misleading. ¹²

In our present case we were misled by recording brachial blood pressure alone and the patient was labelled as having hypotension which in fact was Pseudo-hypotension. Hence , it is advisable to perform additional blood pressure measurement of the ankle which may represent the true cardiac load and blood pressure to avoid a misdiagnosis regarding patient's actual blood pressure .

CONCLUSION

Diagnosing Takayasu arteritis is a challenge and as far as an important parameter like blood pressure is concerned ,the diagnosis could be misleading . Most of the cases of Takayasu arteritis have Hypertension and only a few cases present with hypotension and most of the times it might be just Pseudo-hypotension , as in our case . Frequently the Subclavian artery is involved in patients suffering from Takayasu arteritis and recording of brachial pressure alone is not sufficient and we recommend additional recording of ankle blood pressure as well.

REFERENCES

1. Kerr GS , Hallahan CW , Giordano J , Leavitt RY , Fauci AS , Rottem M , Hoffman GS . Takayasu arteritis . Ann Intern Med: 1994;120: 919-929.
2. Jameson ,Fauci , Kasper , Hauser , Longo and Loscalzo : Harrison's Principles of Internal Medicine Vol.2, 20th Ed.
3. Yadav M.K. , Leeneshwer H , Rishi J.P. Pulseless Cardiomyopathy . Assoc Physicians India 2006 ; 54:814-6
4. Nastri M.V , Baptista L.P , Baroni R.H , Blasbalg R , De Avila L.F , Leite C.C , de Castro C.C , Cerri G.G. Gadolinium-enhanced three-dimensional MR Angiography of Takayasu arteritis. Radiographics 2004 ; 24 : 773-86
5. Weyand CM , Goronzy JJ. Medium and large vessel vasculitis . N Engl Med: 2003 ; 349:160-9
6. Lane SE , Watts r , Scott DG. Epidemiology of Systemic vasculitis. Curr Rheumatol Rep 2005 ; 7 : 270-5
7. Peera MA , Lo Curto M , Elfond M. A case of Takayasu arteritis causing subclavian steal syndrome and presenting as syncope. J Emerg Med 2008 ; 40 : 158-61
8. Bikakcigil M , Aksu K , Kamali S , Ozbalkan Z , Ates A , Karadag O , et al . Takayasu arteritis in Turki –Clinical and angiographic features of 248 patients . Clin Exp Rheumatol 2009 ; 27:59-64
9. Gupta HO , Nanda T , Tiwari A , Meshram V . Takayasu arteritis in Young Female Present with Fever and Hypotension. Int. J. Sci Stud 2919 ; 6 : (12): 245-48.
10. Arend WP , Michel BA , Bloch DA , Hunder GG , Calabrese LH , Edworthy SM , et al . The American College of Rheumatology 1990 , Criteria for classification of Takayasu arteritis. Arthritis Rheum . 1990 Aug 33 (8):1129-34
11. Franz Hafner , Harald Froehlich , Thomas Gary , Kurt Tiesenhausen , Michael Scarpatetti and Marianne Brodmann . Ankel Blood Pressure for Takayasu . Ann Thorac Surg, 2012 ; 93 : 1299-301.
12. Sohn IS , Jang ST , Jin et al . Takayasu arteritis . Heart Vessels 2008 ; 23:209-13.