



**VENTRICULO-PERITONEAL SHUNT AS A PRINCIPAL SINGLE TREATMENT OF NORMAL PRESSURE HYDROCEPHALUS.**

**Clinical Research**

**Ozor II\*** Department of Surgery, Enugu State University of Science and Technology Teaching Hospital, Parklane, Enugu \*Corresponding Author

**Nwokocha K.** Department of Surgery, Enugu State University of Science and Technology Teaching Hospital, Parklane, Enugu

**ABSTRACT**

**INTRODUCTION:** Normal pressure hydrocephalus is a rare condition and one of the treatable causes of dementia that is frequently missed on presentation with differentials like Alzheimers disease, vascular dementia and occasional bladder outlet obstruction and neurogenic bladder being considered first. There is increased prevalence with age. The aim of this paper is to highlight the outcome following VP shunt as the principal single treatment of normal pressure hydrocephalus.

**METHOD:** Recruited retrospectively, 6 patients, treated in the last 5 years in two institutions in Enugu, South-East Nigeria.

**RESULTS:** A total of 6 patients, five (5) males and one (1) female, all above 60years (except for one male who was 48years) were managed. They all presented with the Hakims triad of gait abnormality, urinary incontinence and dementia. MRIs were done as the gold standard and showed ventriculo-sulcal disproportion. Ventriculo-peritoneal shunting was done with resolution of gait abnormalities and urinary incontinence in all the patients. Cognitive function had some marginal improvement generally.

**CONCLUSION:** In the presence of gait abnormalities with or without urinary incontinence and dementia in an elderly patient, there should be a high index of suspicion as there is little awareness especially in other specialties outside neurosurgery. Symptoms can progressively worsen until they become irreversible worsening quality of life for patients in this geriatric population. Early offer of surgical ventriculoperitoneal shunting improve outcome in all these patients.

**KEYWORDS**

hydrocephalus, gait abnormalities, ventriculo-sulcal, cognitive, incontinence

**INTRODUCTION**

Normal pressure hydrocephalus is a rare and poorly understood condition; one of the treatable causes of dementia that is frequently missed on presentation. Differentials like Alzheimers disease, Parkinsons and even vascular dementia are considered first (it can also co-exist with these). It is seen in the elderly population with increasing prevalence with age significantly contributing to morbidity and disability adjusted life years for this population.

Hakim and Adams in 1965 described this condition that typically presents with a triad of gait abnormalities, urinary impairment and sub-acute cognitive decline.

Imaging modality preferred is the magnetic resonance imaging and it shows marked enlargement of cerebral ventricles. It responds favorably to shunting procedures and Cerebrospinal Fluid diversion.

The authors report 6 cases of idiopathic normal pressure hydrocephalus that illustrated the difficulty in making diagnosis, response to treatment and a brief review of its clinical presentation, diagnosis and ventriculo-peritoneal shunt as a principal single treatment of normal pressure hydrocephalus

**AIM;**

To highlight the outcome following use of Ventriculo-peritoneal shunt as the single treatment option for this condition

**METHOD;**

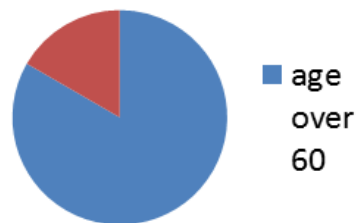
Recruited retrospectively, 6 patients treated in the last 5 years in South Eastern Nigeria.

**RESULTS:**

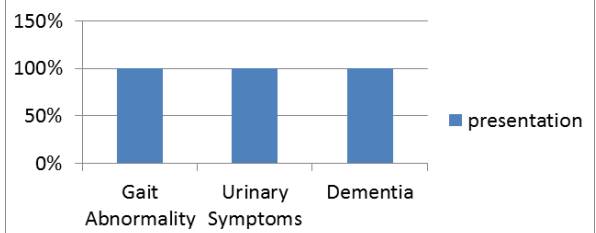
A total of 10 patients, nine (9) males and one (1) female all above 60years (except for one male who was 48years) were managed in the past 5years and all of them presented with the Hakims triad of gait abnormality followed by urinary incontinence and dementia. MRIs were done as the gold standard and showed ventriculo-sulcal disproportion. Ventriculo-peritoneal shunting alone was done with resolution of gait abnormalities and urinary incontinence in all the patients. Cognitive function had some improvement generally. All our patients had good outcome.

<b>Total number</b>	<b>10</b>
Males	9
Females	1

**Age**



**presentation**



Mode of presentation and Clinical response

Symptom	Clinical response	Percentage of patients
Gait Abnormality	Complete	100%
Urinary Symptoms	Complete	100%
Cognitive impairment	Incomplete	100%

**DISCUSSION:**

Normal pressure hydrocephalus (NPH) is a clinical syndrome complex brought about by the buildup of cerebrospinal fluid (CSF). It is characterized by abnormal gait, urinary incontinence and potentially reversible dementia. (Micheal J. Schneck et al, 2017). It is gradually progressive and it is fraught with misdiagnosis. Other causes of cognitive impairment would have to be ruled out. It is mainly found, as seen in our study population, in the 6<sup>th</sup> decade of life. This is in agreement with studies done both within and outside the country. There was however a case report by Armiya'u AY in 2014 on a 40 year old female patient who developed NPH following emotional trauma

(Armiya'u AY et al, 2014).

NPH has many aetiology; Idiopathic, stroke, heads injury, brain tumor and meningitis just to mention a few. All our patients in these series had an idiopathic cause of their NPH. There is a lack of a gold standard in clinical practice and epidemiological research which has contributed significantly to misdiagnosis. However, the Hakim's Triad of; gait abnormality, urinary symptoms and cognitive impairment and ventriculomegaly on MRI should raise a suspicion of this disease entity (J. Andersson et al, 2017) This is in agreement with our findings where all our patients had Hakim's triad in addition to MRI findings. Internationally, a patient is subjected to lumbar taps of about 30mls of CSF or lumbar drainage which relieves symptoms as seen in a case report in London by Conn HO where the patient was misdiagnosed but was subjected to lumbar tap with instantaneous relief of symptoms before conversion to a Ventriculo-peritoneal shunt (Conn H. et al, 2007). There are many tests used to predict possible response to surgery such as MRI of the brain, formalized neurophysiological and gait testing, large -volume lumbar puncture, and prolonged lumbar drainage, but no one test has been validated to rule out potential response to surgery. (David Shprechne, DO, et al, 2008). In this study our patients were not subjected to lumbar taps or drainages in making diagnosis. They all had ventriculo-peritoneal shunt surgeries with marked improvement of symptoms and good outcome.

Ventriculo-peritoneal Shunting, however, has remained the most common therapy for NPH (Meg Verrees et al., 2004). In NPH, the success rate of this procedure varies from 33% to more than 90%. (Gleason PL et al., 1993; Krauss JK et al, 2001; Hebb AO et al, 2001). This wide range in outcome probably reflects variations in patient selection. Examination of the results of multiple studies yields a wide variation in patients response to CSF diversion. According to one review, (Hebb AO et al, 2001); 59% of patients with NPH reported improvement after shunting with a persistent in only 29%.

In another study, (Savolainen S et al, 2002); at one year following VP Shunting in their cohort study of 25 patients 72% of patients had improvement in activities of daily living, 58% improvement in urinary incontinence and a 57% improvement in ambulation. (David Shprecher, DO et al, 2008).

However, in this study, we recorded 100% improvement in both activities, urinary incontinence and cognitive impairment up to at six months follow - up. However a small number of patients involved in this study may be a limitation or account for the sharp disparity in outcome seen in this study compared to some other previous studies.

## CONCLUSION:

In the presence of gait abnormalities with or without urinary incontinence and dementia in an elderly patient, there should be a high index of suspicion as there is little awareness especially in other specialties outside neurosurgery. Symptoms can progressively worsen until they become irreversible worsening quality of life for patients in this geriatric population. Early offer of surgical ventriculo-peritoneal shunting as a sole surgical procedure improves outcome in all these patients.

## REFERENCES

1. Adam OH, Cusimano MD. (2001). Idiopathic Normal pressure Hydrocephalus: A Systemic Review of Diagnosis and Outcome. *Neurosurgery*, 49: 1166-86
2. Andersson J, Rosell M, Kockum K, Soderstrom L and Laurell K. (2017). Challenges in diagnosing normal pressure hydrocephalus. *Evaluation of diagnostic guidelines. eNeurologicalSci*. 7:27-31; doi:10.1016/j.ensci.04.002
3. Armiya'u AY. (2014.) Normal pressure Hydrocephalus with onset following a traumatic experience. *J. Neurol Disord* 2:18:4. doi:10.4172/2329-6895.1000184
4. Conn HO. (2007). Normal pressure hydrocephalus: a case report by a physician who is the patient. *Clin Med (Lond)*; 7(3):296-9
5. David Shprecher DO, Jason Schwab MD and Roger Kurlan MD. (2008). Normal pressure Hydrocephalus: Diagnosis and Treatment. *Curr Neurol neurosc Rep*. 8(5):371-376. doi:10.1007/s11910-008-0058-2
6. Gleason PL, Black PM, Matsumae M. (1993). The Neurobiology of normal pressure hydrocephalus. *Neurosurg Clin. North Am*. 4:667-75
7. Hakim S., Adams RD. (1965). The special clinical problem of symptomatic hydrocephalus with normal cerebrospinal fluid pressure. Observations on cerebrospinal fluid hydrodynamics. *J. Neurol Sci*. 2:307-77.
8. Hebb AO, Cusimano MD. (2001). Idiopathic normal pressure hydrocephalus: a systematic review of diagnosis and outcome. *Neurosurgery*, 49:1166-84
9. Krauss JK, Faist M, Schubert M, Borremans JJ, Lucking CH, Berger W. (2001). Evaluation of gait in normal pressure hydrocephalus before and after shunting. *Adv. Neurol*. 87:301-10
10. Micheal J. Schneck, MD. (2017). Normal pressure hydrocephalus clinical presentation. *Medscape*.
11. Savolainen S, Hurskainen H, Paljarvi L, Alafuzoff I, Vapalahti M. (2002). Five-year outcome of normal pressure Hydrocephalus with or without a shunt: predictive value of the clinical signs, Neuropsychological evaluation and infusion test. *Acta Neurochir*

(Wien). 144:515-23

12. Schwarzschild M, Rordorf G, Bekken K, Buonanno F, & Schmahmann JD. (1997). Normal-Pressure hydrocephalus with misleading features of irreversible dementias: A case report. *Journal of Geriatric psychiatry and Neurology*, 10(2), 51-52