



ANALYSIS OF FUNCTIONAL OUTCOME OF TUBERCULOUS SPONDYLODISCITIS TREATED BY POSTERIOR STABILIZATION

Orthopaedics

Dr. K Senthil Kumar

M S Ortho, Assistant Professor, Department Of Orthopaedics Madurai Medical College

Dr K P Saravanakumar*

M.S Ortho, Associate Professor, Department Of Orthopedics, Government, Theni Medical College *Corresponding Author

ABSTRACT

Vertebral tuberculosis is most common form of tuberculosis and it accounts for 50% of all skeletal tuberculosis .untreated vertebral tuberculosis results in neurological complication. chemotherapy remains main stay of treatment in tuberculosis spine. This study is done to evaluate the function outcome of Tuberculous spondylodiscitis treated with chemotherapy and posterior stabilization. This study is prospective observational study involving a case series of 22 pt with Tuberculous spondylodiscitis who presented in spine out patient department Madurai medical college during the year may 2016 to may 2017 . In our study we followed the patient for 2 year there was a statistically significant change in measures of VAS score , Neurological status till one year follow up and the first year values remain static at 2nd year follow up. Posterior instrumentation is justified by the fact that posterior elements are relatively healthier when compared to the vertebral body. Our prospective observational study on surgical management by posterior stabilization for spinal TB with chemotherapy concluded that the posterior only procedure obtained better clinical outcome .

KEYWORDS

tuberculosis, spinal TB, posterior stabilization, functional outcome

1. INTRODUCTION :

Vertebral tuberculosis is most common form of tuberculosis and it accounts for 50% of all skeletal tuberculosis .untreated vertebral tuberculosis results in neurological complication. chemotherapy remains main stay of treatment in tuberculosis spine. Laminectomy for TB spine results in spine destabilization and worsening of neurological deficit. Radical debridement and anterior column reconstruction was gold standard surgical procedure .but this procedure involves thoracotomy and large volume of blood loss. and morbidity and mortality associated with this procedure is high

2.AIM OF THE STUDY

This study is done to evaluate the function and radiological outcome of Tuberculous spondylodiscitis treated with chemotherapy and posterior stabilization.

3. MATERIAL AND METHODS

Study design

This study is prospective observational study involving a case series of 22 pt with Tuberculous spondylodiscitis who presented in spine out patient department Madurai medical college during the year may 2016 to may 2017

Inclusion/exclusion criteria

Inclusion criteria

All Tuberculous spondylodiscitis pt in the age group 20 to 60 with incomplete neurological deficit or cobbs or angle >20 *, or vertebral body collapse or destruction >30%

Exclusion criteria

Patient unfit for surgery, multiple vertebral Tuberculous osteomyelitis sparing more than 3 vertebra or multiple level involvement, multi drug resistant tuberculosis.

Diagnosing criteria

Patient was initially evaluated with X ray of spine, Hb Total count , Differential count, ESR, CRP, sputum for AFB. GeneXpert assay of sputum, MRI OF SPINE Diagnosis was confirmed by C arm guided Transpedicular biopsy of involved vertebra.

Procedure

Through posterior approach pedicle screw of appropriate size and length as measured on CT inserted proximally and distally for two vertebra above and below one side the pedicle screw is connected to rod on other side. involved vertebra pedicle removed. Through trans pedicular approach granulation removed ,the cavity is filled with morselized bone graft with or with out cage. kyphotic deformity correction done other side pedicle screw connected to titanium rod ,post operatively pt mobilized with hyperextension brace for 3 month .

Anti Tuberculous chemotherapy continued for one year with intensive

phase for 3 month and continuation phase for 9 month

Outcome measure/follow up

pt evaluated neurologically clinically serologically 3 month 6 month 9 month 12th month and 2 year

Table No 1: Functional Parameters

Parameters	Mean	Std. Deviation	Median	IQR	Minimum	Maximum
VAS at Pre op	8.68	.478	9.00	1	8	9
VAS at 1 year follow up	1.47	.697	1.00	1	1	3
VAS at 2 years follow up	1.33	.767	1.00	1	0	3
ESR at Pre op	116.63	20.530	111.00	34	88	158
ESR at 1 year follow up	40.21	9.132	40.00	12	27	59
ESR at 2 years follow up	26.44	7.610	25.00	8.5	18	49

Table No :2 Asia Impairment Scale

Neurological status	ASIA IMPAIRMENT SCALE				
	A	B	C	D	E
Pre op		4	12	4	2
1 year follow up	0	1	1	6	14
2 year follow up	0	0	2	6	14

Statistical analysis

Statistical analysis was performed with IBM SPSS version 16(SPSS Inc., Chicago, IL). Descriptive statistics was computed. The results were presented as mean, standard deviation median and inter quartile range for continuous data and as frequency and percentages for categorical data. Data were tested for normality using Shapiro wilks normality test. Since the data levels were skewed, Preoperative and postoperative measurements at various intervals based on levels of lesion were compared using Mann whitney U test. The results were considered significant with p value less than 0.05

Figure No 1: Pre Op And Post Op – Vas Score

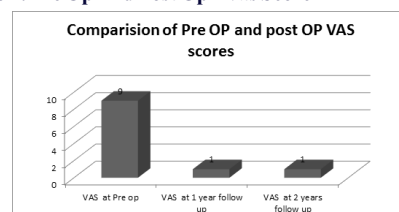
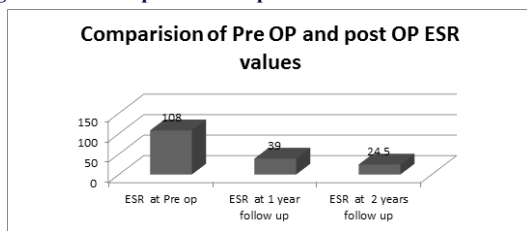


Figure No 1: Pre Op And Post Op – Esr Value

The non parametric Friedman test was used to compare median VAS scores, ESR values, COBB's angle measured at various occasions. A post hoc Wilcoxon signed rank test was used for pair wise comparison at all possible combinations to examine where the differences actually occur. Thus it is a multiple comparison bonferroni correction [p value/ no.of. wilcoxon test used] has been done Post hoc analysis with Wilcoxon signed-rank tests was conducted with a Bonferroni correction applied (0.05/3), resulting in a significance level set at $p < 0.016$.

4.OBSERVATIONAND RESULTS

In our study we followed the pt for 2 year there was a statistically significant change in measures of VAS score ,Neurological status till one year follow up and the first year values remain static at 2nd year follow up ,. But ESR values significantly decreases in each follow up at pre OP, at 1 year and 2 years ($p < 0.001^{**}$) there was significant improvement in neurological status with in one year .20 out of 22 pt become ambulant at the end of 2 year

5.DISCUSSION

The advent of pedicle screw instrumentation allowed spine surgeons to opt for posterior-only surgery. It avoids hazards of violating the thoracic or abdominal cavities. Though Spinal TB is associated with osteopenia . Posterior instrumentation is justified by the fact that posterior elements are relatively healthier when compared to the vertebral body . Titanium implant is associated with poor biofilm formation and hence instrumentation is justified even in active infection. Whether the anterior approach is superior to the posterior approach is still debatable among surgeons. Our prospective observational study on surgical management by posterior stabilization for spinal TB with chemotherapy concluded that the posterior only procedure obtained better clinical and radiological outcomes .

6.CONCLUSION

Tuberculosis is major public health problem in developing country .ATT remains main stay of treatment in tuberculosis including osteo articular tuberculosis. In case of spinal tuberculosis chemotherapy alone is associated with poor results, due to destruction of anterior column and instability ,and hence debridement and anterior column reconstruction and anterior stabilization with chemotherapy gives better result than chemotherapy alone.but this procedure is associated large volume of blood loss.intensive care.complication,mortality and morbidity where as posterior stabilization with transpedicular decompression and anterior column reconstruction through posterior approach gives promising results

7.REFERENCES :

1. Rajasekaran S, Khandelwal G. Drug therapy in spinal tuberculosis. Eur Spine J 2013;22 Suppl 4:587-93.
2. Jain AK. Tuberculosis of the spine: a fresh look at an old disease. J Bone Joint Surg Br 2010;92:905-13.
3. Lee SH, Sung JK, Park YM. Single-stage transpedicular decompression and posterior instrumentation in treatment of thoracic and thoracolumbar spinal tuberculosis: a retrospective case series. J Spinal Disord Tech 2006;19:595-602.
4. Zhang HQ, Li JS, Zhao SS, et al. Surgical management for thoracic spinal tuberculosis in the elderly: posterior only versus combined posterior and anterior approaches. Arch Orthop Trauma Surg 2012;132: 1717-23.