



LATE ONSET POSTPARTUM ECLAMPSIA WITH HELLP SYNDROME & TYPE 1 RESPIRATORY FAILURE

Gynaecology

Dr Neelu Khanna Suri	MBBS, MS Obstetrics & Gynaecology , SGL Charitable Superspeciality Hospital, Garha Road Jalandhar, Punjab
Dr Pawan Kumar Suri*	MBBS, MD, DM Cardiology , SGL Charitable Superspeciality Hospital, Garha Road Jalandhar, Punjab *Corresponding Author
Dr Puneet Singh Perhar	MBBS, MD Respiratory Medicine, Department of Respiratory Medicine, SGL Charitable Superspeciality Hospital, Garha Road Jalandhar
Dr Kanika Kinra	MBBS, Resident Internal Medicine, SGL Charitable Superspeciality Hospital, Garha Road Jalandhar, Punjab

KEYWORDS

INTRODUCTION:

Preeclampsia is defined as the new onset of hypertension and proteinuria after 20 weeks of gestation in a previously normotensive woman [1]. The occurrence of generalized convulsions in a woman with preeclampsia without an alternative identifiable cause is referred to eclampsia. Approximately one-half of all cases of eclampsia occur postpartum [2, 3]. For a long time eclampsia was thought to not occur later than 48 hours after delivery [4]. This opinion was modified due to the onset of postpartum eclampsia occurring more than 48 hours after the onset of the postpartum period in some patients [5, 6] We hereby present a similar case of gravid female with HELLP syndrome with right lower zone consolidation with type 1 respiratory failure

CASE REPORT:

We hereby discuss case of 32Y female who presented with PIH and transverse lie, on the day of admission her period of gestation was 34weeks, her Haemoglobin was 12.7 and platelet count was 87000 , and her liver function test had raised liver enzymes {SGOT/SGPT-998/1275} , her pregnancy was terminated in view of Transverse lie & impending HELLP syndrome, Emergency Lower Segment Cesarean Section was performed, her postop day 1 &2 remained uneventful , on day 3 post op she started desaturating following which she had an episode of seizure, which was treated according to standard protocols of eclampsia management with magnesium sulphate, she was not maintaining vitals and saturation in view of poor GCS she was intubated, even after intubation her consequent blood gas analysis showed hypoxemia, as she already had deranged liver function tests an abdominal ultrasonography was advised, which incidentally showed a large area of consolidation in one lung ,on further investigation after the incidental clue her HRCT Chest {figure 1} Showed large areas of pneumonic consolidation involving various segments of right lower lobe. Probably after the seizure episode or during the episode of seizure she developed aspiration pneumonitis. She was kept on conservative management with broad spectrum antibiotics.

She was kept on ventilator till her general condition recovered she was given higher antibiotics and her xray improved gradually {figure 2}. Though she was extubated after 24 hours yet she needed high flow oxygen for next 2-3 days, with hourly lung exercises. She was discharged in stable condition at 7th postop day.

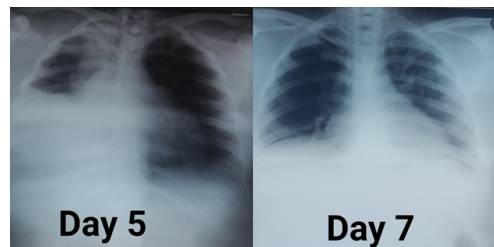
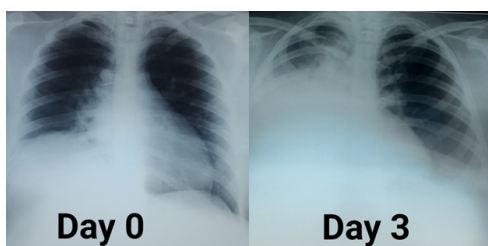


Figure 2

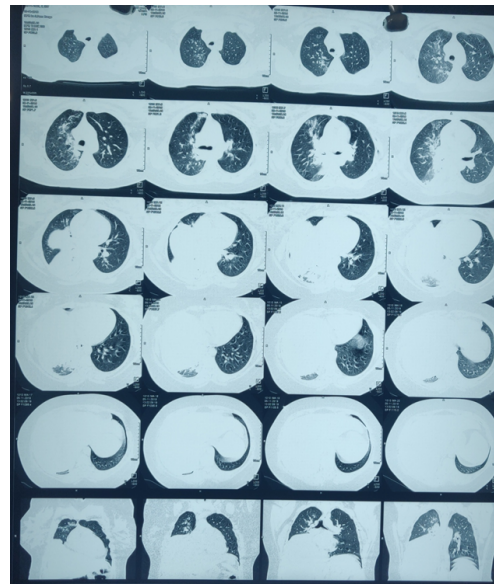

Figure 1

DISCUSSION:

Complications in eclampsia are common and include acute renal failure, acute liver failure, and respiratory complications, such as aspiration pneumonia and acute pulmonary edema [7] Because of the severe complications, the appropriate therapy of eclampsia should be initiated as early as possible. For preventing and treating seizures in eclamptic patients magnesium sulphate is the drug of choice, as it is associated with a significant reduction of recurrent seizures, the risk for pneumonia, and admission to an intensive care unit [8,9]

Mortality rates were also found to be substantially lowered compared to diazepam and tended to be reduced compared to phenytoin treatment [8,9]. This is quite remarkable, since neurologists have a tendency toward using these classic anticonvulsants in patients with

seizures that are due to other causes than eclampsia.

CONCLUSION:

This case emphasizes the importance of early diagnosis of postpartum eclampsia, as early diagnosis and subsequent initiation of the appropriate antihypertensive and anticonvulsant therapy with intensive unit care, prevent severe complications. With the recent trend of discharging new mothers soon after delivery (often within 1 day), patients with eclampsia may present to primary care physicians and emergency departments with early signs and symptoms of eclampsia. The early recognition of the signs and symptoms of postpartum eclampsia may lead to early treatment and fewer complications.

REFERENCES

1. K. Seck and T. Fischer, "Diagnosis and treatment of preeclampsia: overview of international recommendations," *Zeitschrift für Geburtshilfe und Neonatologie*, vol. 213, no. 3, pp. 106–112, 2009.
2. K. A. Douglas and C. W. G. Redman, "Eclampsia in the United Kingdom," *British Medical Journal*, vol. 309, no. 6966, pp. 1395–1400, 1994.
3. B. Sabiri, A. Moussalit, S. Salmi, S. El Youssoufi, and M. Miguil, "Post-partum eclampsia: epidemiology and prognosis," *Journal de Gynecologie Obstetrique et Biologie de la Reproduction*, vol. 36, no. 3, pp. 276–280, 2007.
4. L. C. Chesley, "Blood pressure, edema and proteinuria in pregnancy. 9. Proposal for classification," *Progress in Clinical and Biological Research*, vol. 7, pp. 249–268, 1976.
5. S. L. Lubarsky, J. R. Barton, S. A. Friedman, S. Nasreddine, K. Ramadan, and B. M. Sibai, "Late postpartum eclampsia revisited," *Obstetrics and Gynecology*, vol. 83, no. 4, pp. 502–505, 1994.
6. R. Dziewas, F. Stogbauer, M. Freund et al., "Late onset postpartum eclampsia: a rare and difficult diagnosis," *Journal of Neurology*, vol. 249, no. 9, pp. 1287–1291, 2002.
7. E. V. Kuklina, C. Ayala, and W. M. Callaghan, "Hypertensive disorders and severe obstetric morbidity in the united states," *Obstetrics and Gynecology*, vol. 113, no. 6, pp. 1299–1306, 2009.
8. L. Duley and D. Henderson-Smart, "Magnesium sulphate versus phenytoin for eclampsia," *Cochrane Database of Systematic Reviews*, no. 4, Article ID CD000128, 2003.
9. L. Duley and D. Henderson-Smart, "Magnesium sulphate versus diazepam for eclampsia," *Cochrane Database of Systematic Reviews*, no. 4, Article ID CD000127, 2003.