



ASYMMETRIC EXTRACTION, INTRA ORAL ELASTICS AND TIP BACK MOMENTS IN TREATMENT OF SUBDIVISION MALOCCLUSION.

Dental Science

Dr. Sagar Jivrajani Consultant Orthodontist, "Siddhivinayak", 3- Panchratna park, Rajkot, Gujrat- 360001

Dr. Wasundhara Bhad Professor and Head, Department of Orthodontics, Govt. Dental College & Hospital, Nagpur, Maharashtra- 440003

Dr. Ruchi Mahajan Consultant Orthodontist, Delhi.

ABSTRACT

Treatment of subdivision malocclusion has always been considered difficult as it involves asymmetric biomechanics to treat asymmetric buccal occlusion. Several treatment modalities include asymmetric extractions, asymmetric headgear, functional appliances, unilateral elastic wear and tip back bends have been suggested for its treatment. However, side effects of each one of them often leads to undesirable side effects in treatment. This report shows two cases which have been treated with combination of asymmetric extractions, unilateral elastic wear and tip back bends to correct subdivision malocclusion. Because of the combination of these three components, undesirable side effects were kept to minimum and yielded a better post treatment outcome. Utilizing proper force analysis and accurate biomechanics often leads to good post treatment outcome.

KEYWORDS

INTRODUCTION:

Asymmetric malocclusion correction can often be challenging because it gets difficult to control the side effect of treatment mechanics. Moreover, asymmetric mechanics has to be incorporated on right and left buccal segment to get acceptable end treatment result. Precise and 3 dimensional analysis of force system has to be carried out before initiating treatment mechanics.¹

Asymmetric buccal segment occlusion or Angle's subdivision malocclusion can be result of skeletal, dento-alveolar malocclusion or a combination of both.² Such a malocclusion often results from abnormal axial inclination of molar or a molar rotation.³

Different treatment modalities in correction of asymmetric malocclusion includes unilateral elastic wear, unilateral tip back bends, unilateral fixed functional appliance, unilateral distalization or asymmetric headgear.¹ Unilateral elastic wear can cause unwanted vertical side effects.⁴ Distalization has a better prognosis in horizontal growers as it will lead to improvement in facial esthetics. However, distalization can cause significant loss in anterior anchorage and it depends upon patients compliance. Fixed functional appliance and headgear can induce skeletal changes that might not be necessary in patients having good facial esthetics. Functional appliances can cause over compensation of molar relationship on class I side.⁵

Unilateral tip back bends can be incorporated in a continuous or sectional arches. Using a tip back bend in a continuous arch requires use of trans-palatal arch (TPA) to control the side effects on opposite molar.¹ Palatal root torque in upper incisors and maxillary 1st molar distalization are encountered when used in upper arch and are often desirable.⁶

Asymmetric extractions are preferred over symmetric extraction in subdivision cases.^{7,8} Moreover, mandibular first molar extraction have also been attempted in class III subdivision cases.⁹

Two cases, one with class II subdivision and other with class III subdivision malocclusion were treated using asymmetric extractions, unilateral tip back mechanics in continuous arch and asymmetric elastic wear.

Case-1:

A 16 yr old female patient came with complaint of forwardly placed upper front teeth. On extra-oral examination she had protrusive and potentially competent lips (Fig.1). Intra oral examination revealed she had class I buccal occlusion on right and class III on left side. Second premolar was clinically missing. There was a bulge on lingual aspect of lower left first premolar and first molar. Occlusal film confirmed presence of lower left second premolar impacted lingually. Upper right second premolar was in cross-bite and maxillary arch was narrow.

Both upper and lower incisors were Proclined (Fig. 2). No facial asymmetry was noted. Dento-alveolar asymmetry was attributed to impacted lower second premolar. Functional examination revealed no functional shift of mandible.

All the diagnostic records including photographs, study models, lateral cephalogram, OPG, and occlusal radiograph were gathered at start of treatment. Patient was found to have skeletal class I pattern and vertical growth pattern. Treatment plan consisted of extraction of upper first premolars and lower first premolar on right (class I) side. On left (class III) side impacted second premolar was surgically extracted.

Molar tubes were welded on buccal surface of bands on molars. Pre-adjusted edgewise brackets with MBT 0.022" prescription (Ortho Organizers, USA) was used. After alignment and leveling (Fig.3), a final working wire was placed: 19 X 25" in upper arch and 16 X 22" stainless steel in lower arch (Orthoforce; G&H Wire, Franklin, Ind) which was cinched back. Since the patient was a vertical grower, high TPA was placed throughout the treatment and bite blocks were placed on lower second molars to prevent their eruption.

Tip back bend (20 degree) were given on left side on 16 X 22" SS wire in lower arch distal to first premolar bracket. Unilateral class III elastic (3-4 Oz, Red) wear was prescribed on left side. Extraction spaces were closed with NiTi closed coil springs. Case finished after keeping full slot wire for 21 days on both the arches.

Bilaterally class I molar and canine relationship were achieved with ideal over bite and over jet. Composite build up restorations were done on upper lateral incisors to improve esthetics. Good intercuspation was achieved which ensured stability (Fig. 4 and 5). Corrections were retained with upper wrap around retainer and lower bonded lingual retainer.

Cephalometric progress for the case is shown in table 1.

Table 1: Cephalometric progress of case 1 (measurements are in degree and millimeter)

Cephalometric Parameter	Pre treatment	Post treatment
ANB	4	3
Wits appraisal	3 mm	1mm
B angle	30	32
W angle	52	57
SN-MP	39	36
FMPA	35	31
Y-axis	60	60
LAFH	67	64
Jaraback's ratio	59.13	62.7
Upper incisor-NA	33	30

(Linear)	9.5	5.5
Upper incisor-SN	116	113
Lower incisor-NB	36	25
(Linear)	8.5	4.5
Lower incisor-Apog	6.5	5
IMPA	96	86

Case 2:

A 15 yr old female patient reported with complaint of poor show of face on smile and mal-aligned teeth in upper and lower front aspect. Extra-oral examination revealed straight profile with competent lips. There was no apparent facial asymmetry (Fig. 6). On Intra-oral examination patient had class I molar relationship on left side and class II on right side. Upper left lateral incisor was in cross-bite relationship. Both upper and lower anteriors were crowded (Fig. 7). There was no functional shift.

Diagnostic records including photographs, casts, Lateral cephalogram and OPG were collected at the start of treatment. Skeletally patient had class I relationship and horizontal growth pattern. Upper and lower anteriors had normal inclination. . Treatment plan consisted of extraction of upper first premolars and lower first premolar on left (class I) side. On right (class II) side second premolar was extracted.

Molar tubes were welded on buccal surface of bands on molars. Pre-adjusted edgewise self ligating brackets with MBT 0.022” prescription (Galaxy orthodontics, India) was used. After alignment and leveling (Fig. 8), a final working wire was placed: 19 X 25” in lower arch and 16 X 22” stainless steel in upper arch (Orthoforce; G&H Wire, Franklin, Ind) which was cinched back.

Tip back bend (15 degree) was given on right side on 16 X 22” SS wire in upper arch distal to second premolar bracket. Unilateral class II elastic (3-4 Oz, Red) wear was prescribed on right side. Extraction spaces were closed with power chain. Case finished after keeping full slot wire for 21 days on both the arches. TPA was used to control the side effect of tip back moment on molar on class I side.

Class I canine and molar relationship were achieved on both sides with ideal overbite and overjet with good inter-cuspation (Fig. 9 and 10). Corrections were retained with upper wrap around retainer and lower bonded lingual retainer.

Cephalometric progress for the case is shown in table 2.

Table 2: Cephalometric progress of case 2 (measurements are in degree and millimeter)

Cephalometric Parameter	Pre treatment	Post treatment
ANB	2.5	3
Wits appraisal	1 mm	1mm
B angle	30	32
W angle	54	56
SN-MP	23	23
FMPA	16	17
Y-axis	54	56
LAFH	59	61
Jaraback's ratio	73	71
Upper incisor-NA	23	26
(Linear)	4	4.5
Upper incisor-SN	108	111
Lower incisor-NB	24	27
(Linear)	4	4.5
Lower incisor-Apog	2	3
IMPA	96	95

DISCUSSION:

Comparable results have been achieved using fixed functional appliances such as herbst and forsus in correction of subdivision malocclusion. However, cost of treatment4 and over-correction of molar relationship on class I side5 were major disadvantages. Both the patients were compliant and wore elastics regularly.

Although elastic wear and unilateral tip back moments offer their own side effects and disadvantages, combination of both of these techniques coupled with asymmetric extraction helps in reducing the overall side effects.3 In both of the cases, skewing of maxillary or mandibular occlusal plane was not noted at the end of treatment. TPA

was used in second case to limit the side effect of tip back moment on one molar to another.

Dental inclinations and crowding were corrected in both cases without significantly changing mandibular plane angle. Vertical side effects were controlled or kept to minimum by combining three treatment modalities in correction of subdivision malocclusion.

Proper Force analysis and using accurate biomechanics is important in correction of subdivision malocclusion to limit the side effects.

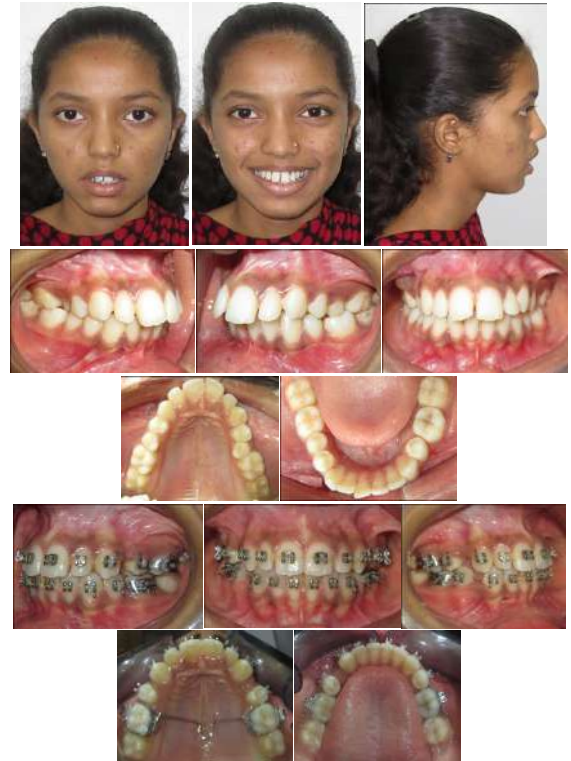

Fig. 3 Alignment and leveling

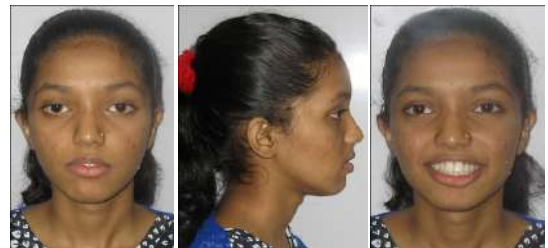

Fig. 4 Post treatment extra-oral photographs

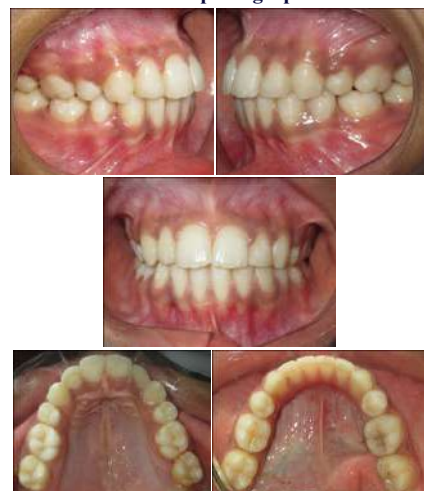

Fig. 5 Post treatment intra-oral photographs




Fig.6 Pre treatment extra-oral photographs

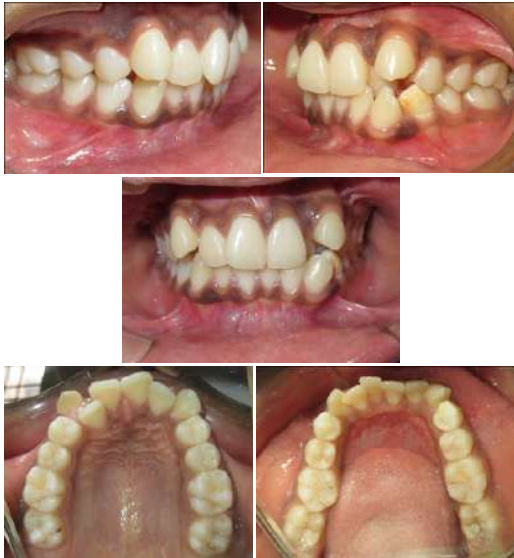

Fig.7 Pre treatment intra-oral photographs

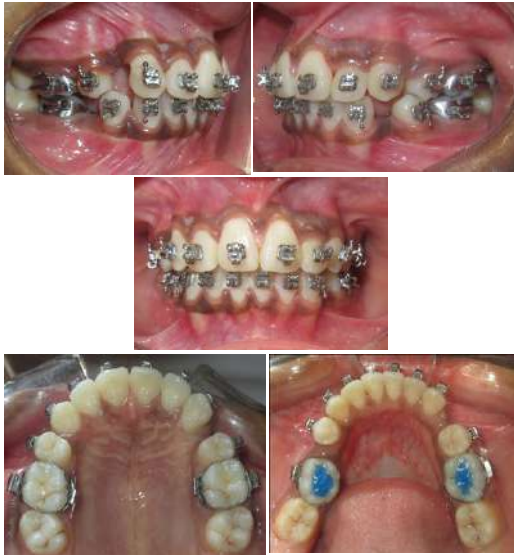

Fig.8 Alignment and leveling



Fig.9 Post treatment extra-oral photographs

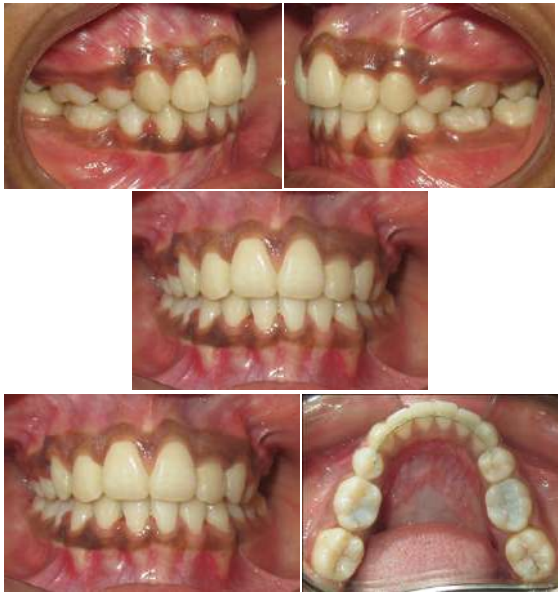

Fig. 10 Post treatment intra-oral photographs

REFERENCES:

1. Shroff B and Siegel S. Treatment of Patients With Asymmetries Using Asymmetric Mechanics. *Seminars in Orthodontics*, Vol 4, No 3 (September), 1998: pp 165-179.
2. Nanda R and Margolis M. Treatment Strategies for Midline Discrepancies. *Seminars in Orthodontics*, Vol 2, No 2 (June), 1996: pp 84-89.
3. Shroff B, Lindauer SJ, Burstone CJ. Class II subdivision treatment with tip-back moments. *EuroJ Orthod* 1997; 19:y93-101.
4. Aras I, Pasaoglu A. Class II subdivision treatment with the Forsus Fatigue Resistant Device vs intermaxillary elastics. *Angle Orthodontist*, Vol 87, No 3, 2017.
5. Bock N, Reiser B, Ruf S. Class II subdivision treatment with the Herbst appliance. *Angle Orthodontist*, Vol 83, No 2, 2013.
6. Janakiraman N, Gill P, Upadhyay M, Nanda R, Uribe F. Response of the maxillary dentition to a statically determinate one-couple system with tip-back mechanics: A prospective clinical trial. *Angle Orthodontist*, Vol 86, No 1, 2016.
7. Janson G, Dainesi EA, Henriques JFC, de Freitas MR, de Lima KJ. Class II subdivision treatment success rate with symmetric and asymmetric extraction protocols. *Am J Orthod Dentofacial Orthop*. 2003;124:257-264.
8. Janson G, Cruz KS, Woodside D, Metaxas A, Roberto de Freitas M, Henriques JF. Dentoskeletal treatment changes in Class II subdivision malocclusions in submentovertex and posteroanterior radiographs. *Am J Orthod Dentofacial Orthop* 2004;126:451-63.
9. Ruellas A, Baratieri C, Roma MB, Izquierdo A, Boaventura L, Rodrigues CS et al. Angle Class III malocclusion treated with mandibular first molar extractions. *Am J Orthod Dentofacial Orthop* 2012;142:384-92.