



## FABRICATION OF HOLLOW MAXILLARY DENTURE AND RESERVOIR MANDIBULAR DENTURE IN A XEROSTOMIA PATIENT.

### Prosthodontics

<b>Swalpa Sharma</b>	III year MDS, Department Of Prosthodontics And Crown And Bridge, Mahatma Gandhi Dental College And Hospital, India
<b>Pooja Jain</b>	III year MDS, Department Of Prosthodontics And Crown And Bridge, Mahatma Gandhi Dental College And Hospital, India
<b>Narendra Padiyar*</b>	Professor and HOD, Department Of Prosthodontics And Crown And Bridge, Mahatma Gandhi Dental College And Hospital, India *Corresponding Author
<b>Pragati Kaurani</b>	Professor, Department Of Prosthodontics And Crown And Bridge, Mahatma Gandhi Dental College And Hospital, India
<b>Soniya Joseph</b>	II year MDS, Department Of Prosthodontics And Crown And Bridge, Mahatma Gandhi Dental College And Hospital, India

### ABSTRACT

Treatment plan is patient-specific and varies according to the history given by the patient. Xerostomia is a condition in which salivary secretion reduces and patient usually shows dry mouth or existence of thick ropy saliva. It can be a result of various causes but is mainly seen in geriatric population as a side effect of the drugs being consumed for whatsoever medical reasons. Residual ridge resorption is a chronic process, and severely resorbed ridges can be seen in large numbers in the geriatric population. This leads to an increased interridge space which thereby increases the weight of the denture, and transfers detrimental forces on the underlying ridges causing further resorption. This article aims to provide a method of fabricating salivary reservoir mandibular dentures in patients suffering from xerostomia, and hollow maxillary dentures in patients with increased interridge distance.

### KEYWORDS

Reservoir denture, Xerostomia, Hollow denture, Increased interridge distance

### INTRODUCTION

Retention, stability and support are the basic principles on which the success of a complete denture relies on. The skill lies in applying these principles efficiently in critical situations'. In large maxillofacial defects and in severely resorbed edentulous ridges, there is a decreased denture bearing area for support, retention and stability. Increase interridge space compounds this problem. To decrease the leverage forces, reduction in the weight of the prosthesis was recommended and was also found to be beneficial<sup>23</sup>

Xerostomia refers to a subjective sensation of dry mouth.<sup>4</sup> It disrupts the normal homeostasis of the oral cavity, leading to changes in the taste, difficulty in speech, difficulty in swallowing and decreased dietary intake. These have a significant negative impact on patient's health and overall quality-of-life<sup>5</sup>. In edentulous patients suffering from xerostomia, salivary substitutes are prescribed. A salivary reservoir can be incorporated into the denture that will maintain continued lubrication of the oral environment by the secretion of this salivary substitute.

This article aims to provide a method for fabricating hollow dentures for the maxillary arch and a salivary reservoir for the mandibular arch as opposed to the conventional methods of fabricating a complete denture.

### CASE REPORT

A 67-year-old male patient reported to the Department of Prosthodontics and Crown and bridge in Mahatma Gandhi Dental College and Hospital, Jaipur with the chief complaint of difficulty in mastication due to dryness of mouth and absence of teeth. Patient had a past dental history of wearing complete dentures since 4 years which caused frictional irritation on the buccal mucosa. No relevant medical history was recorded. Extraoral examination revealed unsupported lips. Intraoral examination revealed severely resorbed maxillary and mandibular edentulous residual ridges (Fig 1,2) with increased interridge distance (Fig 3). Labial, buccal mucosa, hard palate, soft palate and floor of the mouth were normal. The patient also showed decreased salivary flow and a lesion on buccal mucosa suggestive of Leukoplakia. Treatment options were discussed with the patient and informed consent was obtained for the agreed treatment, which included rehabilitation of the upper arch with conventional hollow complete denture and reservoir denture in the lower arch.

### TECHNIQUE FOR MAXILLARY DENTURE.

The bilaterally balanced maxillary denture was fabricated up to the

trial denture stage in the conventional manner. The land area of the cast was indexed using a conical bur (fig 4) and the trial denture was sealed to the definitive cast. The trial denture was then duplicated in irreversible hydrocolloid and poured in dental stone (Fig 5). A template of this duplicated trial denture was made by adapting 0.5 mm thermoplastic sheet. Followed by this, the trial denture was processed in the standard manner up to the wax elimination stage. Thereafter, two layers of baseplate wax were adapted to the definitive cast in the drag, conforming to the border extensions. A second flask was then used to invest this baseplate wax and processed in conventional manner. After deflasking, the thermoplastic template was placed on the definitive cast using the indices in the land area as seating guides after which an endodontic file with a rubber stop was used to measure the space between the matrix and the processed base (Fig. 6). Following this, vinyl polysiloxane putty [Zetaplus] was mixed and adapted on the base and shaped to the approximate contours of the matrix (Fig. 7). The polymerized putty was shaped with a bur to leave 2-3 mm of space between the putty and matrix. An additional 1 mm space was provided over the tooth portion of the denture. The putty was fixed to the base using cyanoacrylate. The original cope was then resealed on the drag and verified for complete closure of the flask. Thereafter, acrylic resin was packed over putty and processed. The processed denture was recovered in the usual manner. After finishing the denture, two openings were cut with a bur into the denture base distal to the most posterior tooth (Fig 8). The silicone putty was removed using a sharp instrument and thick orthodontic wire. The openings were widened as necessary, to facilitate access. After complete removal of putty, openings were covered with pink autopolymerising resin. The denture was polished in the usual manner and the seal was verified by immersing the denture in water. (air bubbles should not be evident after immersing the denture in water). Hollow dentures are verified by dipping them in water. Hollow dentures float (fig 9) whereas conventional dentures submerge in water. (fig 10)

### TECHNIQUE FOR MANDIBULAR DENTURE.

The bilaterally balanced mandibular denture was fabricated up to the try in stage in the conventional manner. Processing of the mandibular denture was carried out the same way as that of maxillary denture (Fig 11, 12). However, putty was adapted only on the posterior 2/3<sup>rd</sup> and anterior 1/3<sup>rd</sup> was left intact.(Fig 13). Stainless steel orthodontic wire was inserted into the reservoir space to verify space for the salivary substitute. (Fig 14). Salivary substitute egresses out of the openings through capillary action. Patient was instructed on how to inject the salivary substitute (ICPA- Wet mouth) into the reservoir space and refill it at regular intervals.

**DISCUSSION.**

Retention of complete denture depends on various factors such as adhesion cohesion, interfacial surface tension, and saliva plays an important role for these factors to come into effect. Patient acceptability also increases when the denture is placed in a lubricated environment. Therefore, this has to be given special consideration while rehabilitating a patient with xerostomia. Providing a salivary reservoir in the denture aids to this cause and can provide palliative care by constantly secreting a salivary substitute which will keep the oral tissues lubricated.

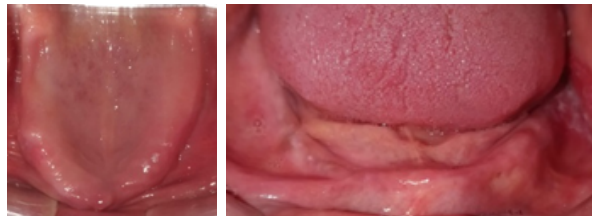In severely resorbed residual ridges, the interridge area inadvertently increases. The surface area of denture increases when interridge distance is increased, which thereby makes the denture heavy. Hollow maxillary complete denture considerably reduces the weight of the prosthesis. This prevents transmission of harmful forces which would otherwise be transmitted from a conventional prosthesis to the underlying tissues. Hence hollow dentures are a viable option in cases with severely resorbed residual ridges wherein the facial height needs to be restored.

This technique for hollow denture and salivary reservoir overcomes the disadvantages of the older techniques. Problems with leakage and difficulty in gauging resin thickness are overcome<sup>6</sup>.

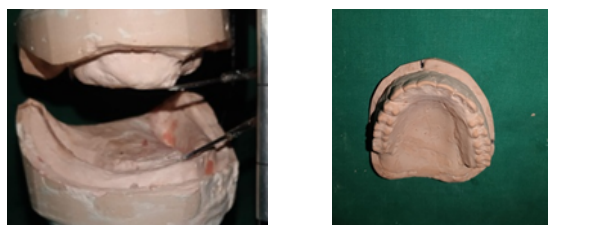
Spacer recovery is easier. Space for salivary substitute can be maintained. Through the use of putty, the thickness of resin can be controlled. This ensures even depth, and prevents deformation. In this technique silicone putty was used as a spacer because it is stable, it can be carved, and it does not adhere to acrylic resin.<sup>7</sup>

**CONCLUSION**

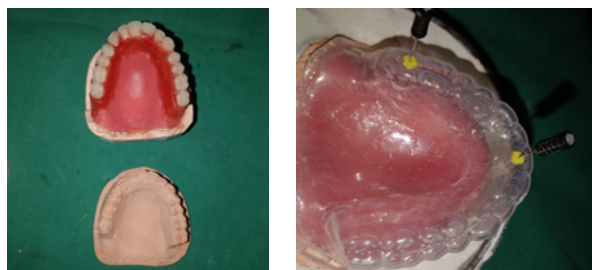Any treatment extended to the patient should not only resolve the immediate problems faced by the patient, but also safeguard the future of the underlying tissues and surrounding structures. This case was treated prosthetically to meet the requirements of the patient and also to further prevent any detrimental effects. The salivary reservoir ensured lubrication of oral tissues to tackle the existing xerostomia, and ensure a successful prosthesis, and the hollow denture reduced stresses placed on residual ridges, which would aid in reducing the rate of resorption of residual ridges, hence nurturing the health of vital oral structures, and preserving them.



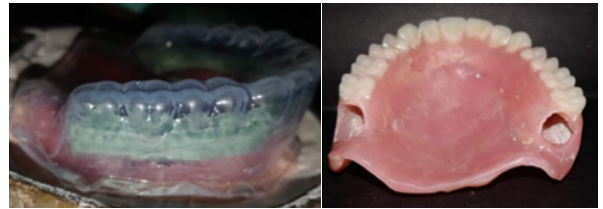**Fig 1 - Edentulous Maxillary ridge. Fig 2 - Edentulous Mandibular ridge**



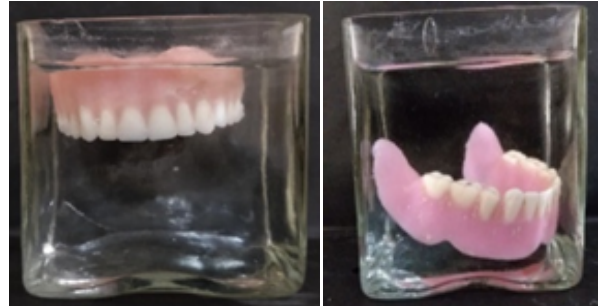**Fig 3 - Interridge distance. Fig 4 - Indexing of cast**



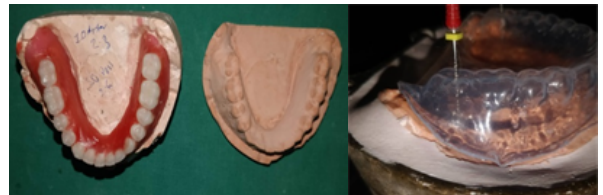**Fig 5 - Duplication of cast. Fig 6 - Space measured between matrix and base**



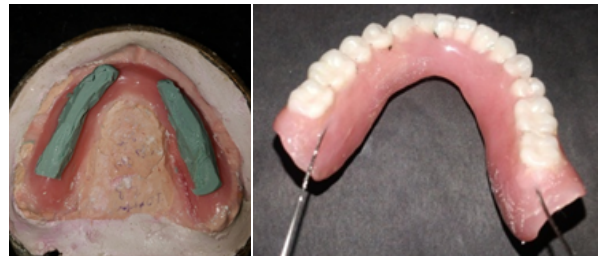**Fig 7 - Putty adapted on base. Fig 8 - Openings made to retrieve putty**



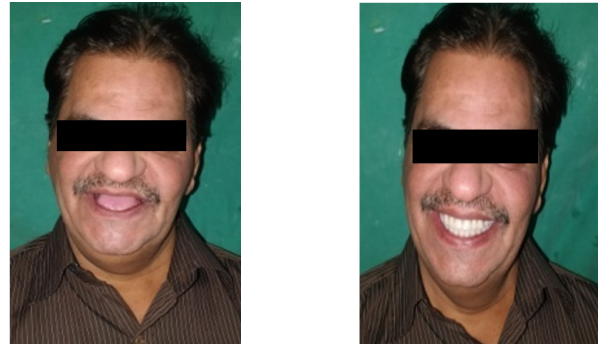**Fig 9 - hollow denture floats. Fig 10 - Conventional denture submerges**



**Fig 11 - Duplication of Mandibular cast. Fig 12 - Space measured with endodontic file**



**Fig 13 - Putty adapted on posterior 2/3<sup>rd</sup>. Fig 14 - Salivary space verified with orthodontic wire.**



**Pre-op Post-op**

**REFERENCES**

1. Kaira LS, Singh E, Jain M, Mishra R. Light weight hollow maxillary complete denture: A case series. J Orofac Sci 2012;4:143-7
2. El Mahdy AS. Processing a hollow obturator. J Prosthet Dent 1969;22:682-6.
3. Brown KE. Fabrication of a hollow-bulb obturator. J Prosthet Dent 1969;21:97-103
4. Neville BW, Damm DD, Allen CM, Bouquot JE. 2nd ed. Philadelphia: W.B Saunders Company; 2002. Oral and Maxillofacial Pathology; p. 356. 398
5. Brosky ME. The role of saliva in oral health: Strategies for prevention and management of xerostomia. J Support Oncol. 2007;5:215-25
6. Usha Radke, Darshana Mundhe, Hollow Maxillary Complete Denture; J Indian Prosthodont Soc. 2011 Dec; 11(4): 246-249.
7. Jhanji A, Stevens ST. Fabrication of one-piece hollow obturators. J Prosthet Dent. 1991;66:136-138