



A STUDY ON VARIOUS SHADES AND GRADES OF MILIARIA RUBRA

Dermatology

Shreya Moozhiyil

Junior Resident, Department of Dermatology, Venereology & Leprosy, Sree Balaji Medical College & Hospital, Bharath University, No.7, Works road, Chromepet, Chennai 600044, Tamil Nadu, India.

Prof. Jayakar Thomas*

HOD & Professor, Department of Dermatology, Venereology & Leprosy, Sree Balaji Medical College & Hospital, Bharath University, No.7, Works road, Chromepet, Chennai 600044, Tamil Nadu, India. *Corresponding Author

ABSTRACT

Background: The study was done to analyse the various presentations of miliaria rubra.

Methods: A total of 30 patients clinically diagnosed with miliaria rubra were evaluated clinically and the results were obtained.

Results: Of the 30 (16 female and 14 male) patients diagnosed with miliaria rubra, 5 patients had just papules, 10 had Miliaria rubra with exfoliation, 6 had erythema, 4 had perioritis, 2 had folliculitis and 3 had associated eczema. Among the 30 patients, 28 of them presented with pigmented lesions and 2 presented with hypopigmented lesions.

Conclusion: There are a few studies showing the different presentations of miliaria rubra. In this study we see the patterns as well as the colours in which it presents.

KEYWORDS

Miliaria rubra, perioritis, exfoliation, folliculitis, eczema, hypopigmentation, pigmentation.

INTRODUCTION

Miliaria is the commonest sweat gland disorder seen in the tropics. It can occur as an acute or subacute skin condition due to the obstruction of the eccrine sweat glands leading to leakage of sweat into the epidermis¹. It's mostly found in hot and humid environments with both sexes equally affected². The incidence of this condition is more during the summer season³.

It can affect any area of the body, with neck and trunk being the commonest in adults⁴. It usually presents as small, discrete, non-follicular, erythematous papules. In severe cases, sheets of erythema is seen. Rarely, they can also present as folliculitis, perioritis and be associated with eczemas.

The course is usually self limiting, but can go into complications like secondary bacterial infection, miliaria pustulosa, frank impetigo and erythroderma.

The diagnosis is usually clinical. It should be differentiated from superficial folliculitis and other rashes.

Treatment is mostly conservative and includes emollients. Topical antibiotics can be given in infected cases. Oral ascorbic acid 500mg twice daily has been found to decrease the severity of the disease⁵. Isotretinoin is successful in recalcitrant cases.

METHODS

Study Design: Cross sectional study.

Study Area: Skin Outpatient Department at Sree Balaji Medical College and Hospital

Study Population: All patients attending skin OPD, clinically diagnosed with miliaria rubra

Study Method: Observational study.

Sample Size: 30

Exclusion criteria:

Not consenting for the study.
Not having Miliaria Rubra

Inclusion criteria:

Those consenting to the study.
The recruited patients were subjected to the following,
(A) Full History Taking
(B) Thorough General Dermatological Examination.
© Photographs.

Study procedure: Each patient was given a written informed consent and the study was explained in detail. Once a detailed clinical examination was done, photographs were taken.

The results obtained were tabulated in Microsoft Excel and analysed using SPSS software.

RESULTS

Of the 30 (16 female and 14 male) patients with miliaria rubra, 5 had just papules, 10 had Miliaria rubra with exfoliation, 6 had erythema, 4 had perioritis, 2 had folliculitis and 3 had associated eczema (figure 3). Among the patients studied, 28 of them had pigmented lesions and 2 had hypopigmented lesions (figure 5).

The study showed that the condition was present in all age groups ranging from 1 – 81 years. It was more common in the age group ranging from 31 – 60 years (figure 1). Figure 4 shows the common presentations in each age group.

DISCUSSION

Many observational studies have shown that as miliaria rubra is a sweat gland obstruction disorder, it can present in various ways depending on the degree of obstruction. This was proved by a study done by Walter B. Shelley⁵. Our study is consistent with this and shows various patterns in which miliaria rubra can presents.

An experimental study done by Walter B and et al⁵ showed that hyperpigmented lesions are more common than hypopigmented which is same as in our study.

Another study done by Robert Carter⁶ showed that the mean age group affected was between 31-37 years, which is similar to this study which shows an increase in cases in the age group ranging between 31-60 years.

Out of the 30 patients studied, 16 were females and 14 males, showing that both genders have almost equal predilection for the condition.

Hence, this study shows that miliaria rubra can occur in various patterns, and is mostly a pigmented condition.

ACKNOWLEDGEMENTS

None

DECLARATIONS

Funding: None

Conflict of interest: None declared

Ethical approval:

Figure 1: Distribution of miliaria in various age groups

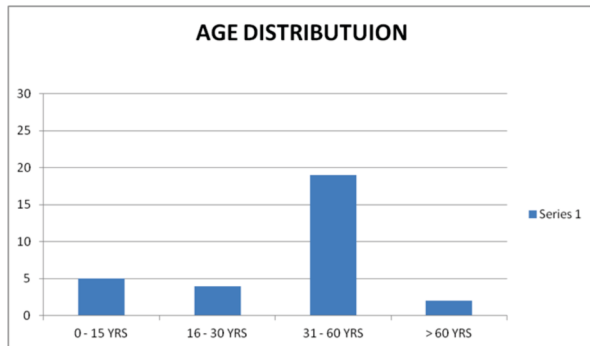


Figure 2: gender distribution

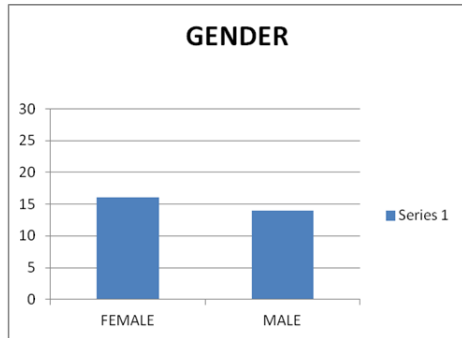


Figure 3: bar chart showing various presentations of miliaria rubra

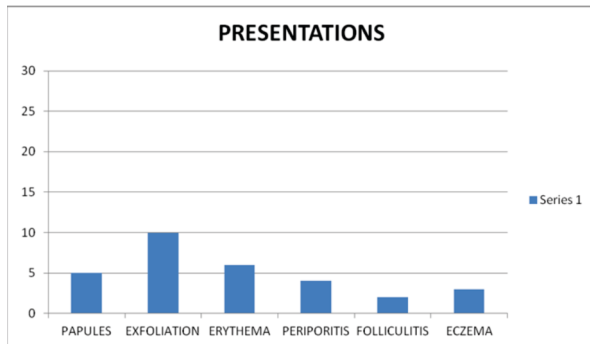


Figure 4: bar diagram showing various pattern in each age group

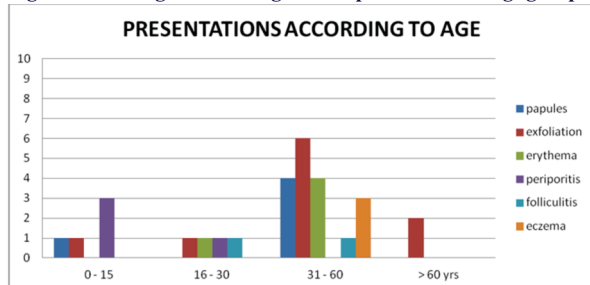


Figure 5: shows the pigment changes in miliaria.

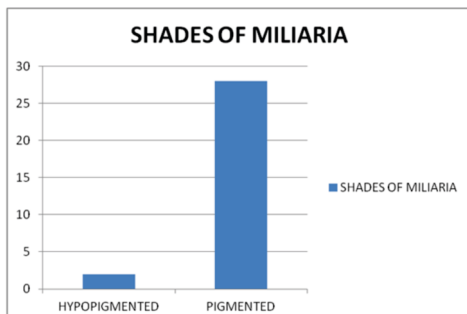
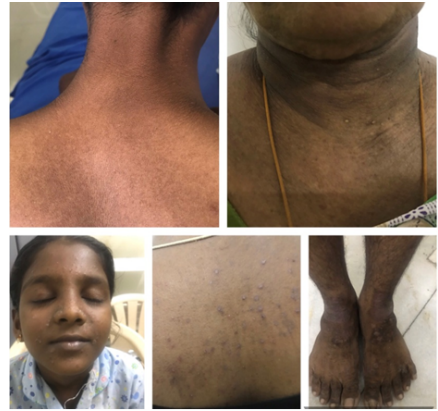

Figure 6: shows the different patterns of miliaria rubra.



REFERENCES

- Hözlle ER, Kligman AM. The pathogenesis of miliaria rubra. Role of the resident microflora. The British journal of dermatology. 1978 Aug;99(2):117-37.
- Champion RH. Disorders of sweat glands. Textbook of Dermatology. 1992:1745-62.
- Sachdeva M, Kaur S, Naggal M, Dewan SP. Cutaneous lesions in new born. Indian Journal of Dermatology, Venereology, and Leprology. 2002 Nov 1;68(6):334.
- Wenzel FG, Horn TD. Nonneoplastic disorders of the eccrine glands. Journal of the American Academy of Dermatology. 1998 Jan 1;38(1):1-20.
- Shelley WB, Horvath PN, Weidman FD, Pillsbury DM. Experimental miliaria in man: I. Production of sweat retention anidrosis and vesicles by means of iontophoresis. Journal of investigative Dermatology. 1948 Oct 1;11(4):275-91.
- Carter R, Garcia AM, Souhan BE. Patients presenting with miliaria while wearing flame resistant clothing in high ambient temperatures: a case series. Journal of medical case reports. 2011 Dec;5(1):474.