



MORPHOMETRIC STUDY OF OCCIPITAL CONDYLES IN INDIANS

Anatomy

Subhathraa G	Final year BDS student, Amrita School of Dentistry, Amrita Vishwa Vidyapeetham, Kochi, Kerala, India
Dr Geetha S G*	Clinical Assistant Professor, Department of Anatomy, Amrita School of Medicine, Amrita Vishwa Vidyapeetham, Kochi, Kerala, India *Corresponding Author
Dr Rathi Sudhakaran	Clinical Professor, Department of Anatomy, Amrita School of Medicine, Amrita Vishwa Vidyapeetham, Kochi, Kerala, India

ABSTRACT

Introduction: The knowledge of morphometric variations of occipital condyles would be useful to interventional radiologists and neurosurgeons. **Aim:** To analyze the variations in shape, size and position of the occipital condyles in human skulls.

Materials and Methods: The study was done on 81 dry human adult skulls of unknown sex obtained from the bone library in the Department of Anatomy, AIMS, Kochi. The shape, maximum length and width of right and left condyles, distance of each condyle from foramen magnum and the intercondylar distance were measured and tabulated. The data was statistically analyzed.

Result and Conclusion: The mean values for the parameters were obtained. The most commonly observed shape of the condyle was oval. The mean width, distance from the posterior tip of condyle to opisthion and distance of the anterior tip of condyle to basion on right and left were significant.

KEYWORDS

Occipital condyles, foramen magnum, transcondylar approach.

INTRODUCTION:

Occipital condyles (OC) are downward protrusions on the inferior surface of the condylar part of the occipital bone on the sides of foramen magnum (FM) articulating with the superior articular facets of the atlas forming atlanto-occipital joint. This joint is the only one of its kind which determines the steadiness of the cranio-vertebral junction (CVJ). Treatment of the tumours at CVJ and around the FM is difficult due to its position and its intricate anatomic relations. Common lesions found in this region are extradural and intradural tumours, lesions of the vertebral artery, rheumatoid disease and malformations of CVJ, synovial cysts, infections, syringobulbia and intrinsic lesions mostly demyelination^[1]. They can be reached by a dorsal approach or a transcondylar approach (TCA) piercing suboccipital muscle or the OC above the atlanto-occipital junction and below the hypoglossal canal^[2,3,4]. This would reduce the depth of the surgery and provide better visibility of the inferior clivus and the ventrolateral part of the FM without any brain retraction^[5]. Since partial OC resection is often an important step in TCA it is important to know the bony extent of the condyles for the TCA^[5,6]. The aim of this study is to analyze the variations in shape, size and position of the right and left occipital condyles in dry human adult skulls.

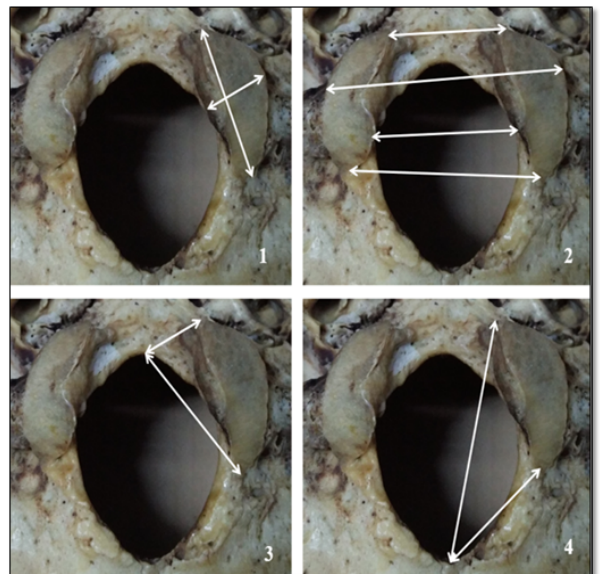
MATERIALS AND METHODS:

This study was done on 81 dry human adult skulls of unknown age and sex obtained from the bone bank in the Department of Anatomy, AIMS, Kochi. Only complete skulls with intact occipital bone and temporal bone were included in the study. The intermastoid distance (from the lateral border of right mastoid to lateral border of left mastoid) of each skull was measured using a digital vernier calliper. The skull and the camera with fixed focal length were positioned at a definite distance and photographs were taken. Using the photo measure software provided by Microsoft Office, and keeping the intermastoid distance as the required reference measurement, the following parameters were measured

1. Length (L) of OC (Right and Left)
2. Width (W) of OC (Right and Left)
3. Distance from anterior tip of condyle to basion (AB) (Right and Left)
4. Distance from anterior tip of condyle to opisthion (AO) (Right and Left)
5. Distance from posterior tip of condyle to basion (PB) (Right and Left)
6. Distance from posterior tip of condyle to opisthion (PO) (Right and Left)
7. Anterior intercondylar distance (anterior tip of right condyle to

anterior tip of left) (AICD)

8. Posterior intercondylar distance (posterior tip of right condyle to posterior tip of left) (PICD)
9. Lateral intercondylar distance (LICD) – Distance between the most prominent points on the lateral borders of condyles
10. Medial intercondylar distance (MICD) - Distance between the most prominent points on the medial borders of condyles



The figures show the parameters measured

1. Length and width of OC
2. Intercondylar distances
3. Anterior tip to Basion and Posterior tip to Basion
4. Anterior tip to Opisthion and Posterior tip to Opisthion

The shapes of the occipital condyles were also noted on each side. The parameters measured were tabulated and statistically analysed for mean, standard deviation (SD), and (p value) significance. The mean values were correlated with the intermastoid distance. A 'p' value <0.05 was taken as statistically significant.

RESULTS:

Morphometric results of the present study are tabulated in Table 1

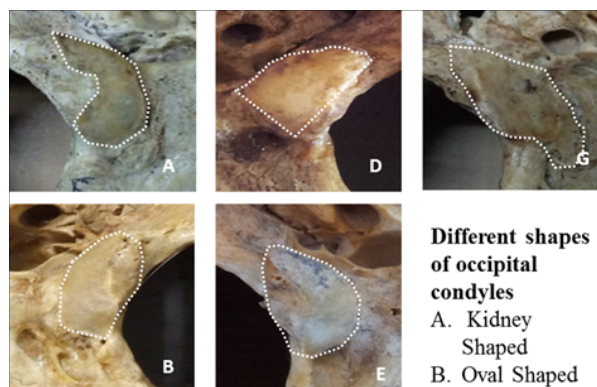
Table 1: morphometric Results Of The Present Study

PARAMETERS	Side	Mean (mm)	SD (mm)	Range (mm)
Length	Left	20.28	4.11	10.64-39.86
	Right	20.25	3.57	10.34-29.14
Width	Left	11.47	2.07	6.81-17.67
	Right	11.10	2.05	7.14-15.85
AB	Left	10.37	2.60	4.67-22.00
	Right	9.64	1.78	6.89-17.89
AO	Left	35.67	4.41	26.85-52.12
	Right	35.29	4.69	19.40-51.17
PB	Left	24.18	3.14	17.59-31.60
	Right	23.74	3.03	18.34-31.92
PO	Left	18.64	3.74	10.45-29.24
	Right	24.49	3.35	17.00-37.35
AICD		18.44	3.47	10.45-29.24
PICD		36.88	5.04	27.04-52.39
MICD		23.23	3.77	10.99-31.97
LICD		41.40	4.82	25.51-53.39

AB: Distance from Anterior tip of OC to Basion; AO: Distance from Anterior tip of OC to Opisthion; PB: Distance from Posterior tip of OC to Basion; PO: Distance from Posterior tip of OC to Opisthion; AICD: Anterior Intercondylar distance; PICD: Posterior Intercondylar distance; MICD: Medial Intercondylar distance; LICD: Lateral Intercondylar distance

The shapes of OC were studied and classified into seven types. They are

1. Oval
2. Round
3. Triangular
4. S' shaped
5. Kidney shaped
6. 8' shaped
7. Deformed.



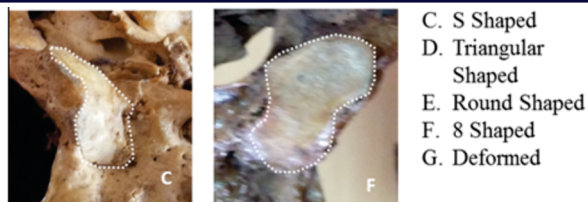Different shapes of occipital condyles
 A. Kidney Shaped
 B. Oval Shaped
 C. S Shaped
 D. Triangular Shaped
 E. Round Shaped
 F. 8 Shaped
 G. Deformed

Table 3: Comparison of length and width of OC between other studies

Study	Archana et al	S kavitha et al	Anil kumar et al	Sanjukta Sahoo et al	Joseph et al	Bozbuga et al	Naderi et al	Present study
Length – Right (mm)	21.83	21.97	23.24	22.45	22.3	23.1	23.6	20.25
Length – Left (mm)	22.19	22.34	24.6	22.65	22.75	22.9	23.2	20.27
Width – Right (mm)	11.07	13.05	12.31	12.55	11.5	11.3	10.6	11.1
Width – Left (mm)	11.42	13.03	12.98	12.92	11.5	11.4	10.6	11.47

The results of the mean distance between the anterior tip of the condyle to basion on right and left sides correlate with the results of Naderiet al^[9] and Sneha Guruprasad et al^[13] who reported it as an average value of 10.8mm and 12mm respectively. On the other hand, the results of mean distance between the posterior tip of condyle to basion on right and left sides are slightly deviating from that of Naderiet al^[9] and Sneha Guruprasad et al^[13] who had recorded higher values as 28mm and 27mm respectively. The mean distance between the anterior tip of condyle to opisthion and posterior tip of condyle to opisthion on right and left sides was found to be similar to Naderiet al^[9] who reported it as 39mm and 26.4mm respectively. Conversely, Joseph et al^[14] had comparatively higher values who found the mean distance between anterior tip of condyle to opisthion as 40.9mm and 42.1mm on right and left sides respectively and posterior tip of condyle to opisthion on right and left sides as 27.87mm and 27.94mm respectively.

The mean AICD was found to be similar to that of Anil Kumar et al^[15]



37.8% was of oval shape and 2.4% was of '8' shape. The frequency of shapes of OC are tabulated in Table 2.

Table 2: The Frequency Of Different Shapes Of Oc

Type	'8' shaped	Deformed	Kidney shaped	Oval	Round	's' shaped	Triangular
Left (in %)	2.4	3.7	13.4	40.2	8.5	15.9	14.6
Right (in %)	2.4	3.7	15.9	35.4	19.5	17.1	4.9
Total (in %)	2.4	3.7	14.65	37.8	14	16.5	9.75

35.80% of OC showed symmetry in their shapes and 64.20% of OC were asymmetrical. OC were categorised according to their length as follows

1. Short - less than 20mm (L),
2. Moderate -20mm to 26mm (L)
3. Long - greater than 26mm (L).

In the present study, 44.44% of OC were short, 51.85% were moderate and 3.7% were long.

The distance between anterior tip of OC to opisthion and the distance between posterior tip of OC to basion shows positive correlation with intermastoid distance.

DISCUSSION:

For easy access to the spinomedullary junction and exposure of neural and vascular lesions in the region, a posterior trans-condylar approach is often the surgeon's choice^[11]. To maintain a greater stability of the occipitocervical joint postoperatively, it is appropriate to understand the morphological variants of OC. This is because the biomechanical effects of partial condylectomy differ among the variant types of OC. It is also important to reduce the depth of the surgical drilling and extent of retraction of neural tissue^[7, 8]. Longer condyles or kidney shaped condyles may require extensive resection than shorter ones and round condyles^[9]. In the present study, the mean value of the length of OC was 20.27mm and 20.25mm on left and right respectively whereas the width of the OC was 11.47mm and 11.10mm on left and right respectively. A comparative study of length and width of OC with results recorded by other researchers^[9-13] is shown in Table 3.

and Sanjukta Sahoo et al^[10] with values 17.63mm and 20.31mm respectively and slightly lesser than that of Sneha Guruprasad et al^[13] with value 21 mm. The mean PICD was found to be lesser than that of Sneha Guruprasad et al^[13], Anil kumaret al^[15] and Sanjukta Sahoo et al^[10] with value 39mm, 42.02mm and 41.17mm respectively. The MICD and LICD slightly deviate from the results obtained by Sneha Guruprasad et al^[13] who reported them as 26mm and 45mm.

On statistical analysis, it showed that the width, the distance between the anterior tip to basion and the distance between the posterior tip to opisthion were bilaterally significant. Also the intermastoid distance had significant correlation with distance between the anterior tip to opisthion and the distance between the posterior tip to basion on both the sides.

The most common shape of OC in the present study was recorded to be oval while crescent and oval shapes were the most common in study

done by Kavitha *et al*^[1] who recorded the shapes as oval, oblong, crescent and rhomboid.

CONCLUSION:

The mean length and width of OC are greater on left side as compared to right side. In transcondylar approach for the treatment of glossopharyngeal neuralgia, vertebral artery or posterior inferior cerebellar artery aneurysm and intradural tumours around foramen magnum, the results of this study would be of assistance to neurosurgeons for planning surgical interventions involving skull base, secure the neurovascular structures and prevent complications like haemorrhage, atlanto-occipital instability, etc. The results of this study may also be of value to radiologists, orthopaedicians and anatomists.

REFERENCES:

1. Cross J, Coles A.(2002) Suppliers of advanced neuroembolization coils. *AdvClinNeurosci Rehabil.*;16-7
2. Al-Mefty O, Borba LA, Aoki N, Angtuaco E, Pait TG.(1996) The transcondylar approach to extradural nonneoplastic lesions of the cranio vertebral junction. *Neurosurg*;84: 1-6.
3. Tedeschi H and Rhoton ALJR.(1994) Lateral approaches to the petroclival region. *SurgNeurol.* 41: 180-216.
4. Wen HT, Rhoton AL Jr, Katsuta T, de Oliveira E.(1997) Microsurgical anatomy of the transcondylar, supracondylar, and paracondylar extensions of the far-lateral approach. *J Neurosurg* 87:555-585
5. Bertalanffy H and Seeger W. (1991) The dorsolateral, suboccipital transcondylar approach to the lower clivus and anterior portion of the craniocervical junction. *Neurosurg* 29:815.
6. Sen CN, Sekar LN.(1991) The surgical management of anteriorly placed lesions at the cranio-vertebral junction: an alternate approach. *ActaNeurochir (Wien).*108:70.
7. Matsushima T, Natori Y, Katsuta T, Ikezaki K, Fukui M and Rhoton 11 AL (1998) Microsurgical anatomy for lateral approaches to the foramen magnum with special reference to transcondylar fossa (supracondylar transjugular tubercle) approach. *Skull Base Surgery.* 8: 119-125.
8. Mintelis A, Sameshima T, Bulsara KR, Gray L and Friedman A (2006) H 12- Fukushima T: Jugular tubercle: Morphometric analysis and surgical significance. *J Neurosurg.* 105: 753-757.
9. Naderi S, Korman E, Citak G, Guvencer M, C Arman M, M S et al.(2005) Morphometric analysis of human occipital condyle. *ClinNeurolNeurosurg.* 107, 191-199.
10. Archana K. Tale, Pratima R. Kulkarni , SanobarIsmutullaShaikh , Santosh S.(2016) Morphometric study of the occipital condyle and its surgical importance. *Int J Anat Res, Vol 4(1):1802-05. ISSN 2321-4287*
11. S. Kavitha, Shanta Chandrasekaran, A. Anand, K.C. Shanthi.(July 2013) Morphometric study of occipital condyles in adult human skulls. *IJCRR*; 5(15):31-34.
12. Bozbuga M, Ozturk A, Bayraktar B, Ari Z, Sahinoglu K, Polat G.(1999) Surgical anatomy and morphometric analysis of the occipital condyles and foramen magnum. *Okajimas Folia AnatJpn.* 75, 329-334.
13. SnehaGuruprasadKalthur, SupriyaPadmashali, Chandni Gupta, and Antony S. Dsouza.. (2014 Apr-Jun)Anatomic study of the occipital condyle and its surgical implications in transcondylar approach. *J Craniovertebr Junction Spine*; 5(2): 71-77.
14. Joseph Naiem.S Aziz and Ahmed Khaled Al-Hrabi. (2016) Morphological study of the foramen magnum and occipital condyle and its surgical implications in transcondylar approach. *ISSN: 2312-5365 print.*
15. Anil Kumar and Mahindra Nagar. (2015) Human adult occipital condyles: A Morphological analysis. *Journal of medical and health sciences.* ISSN: 2319-98
16. Sanjukta Sahoo , Sanjay Kumar Giri , Sitansu K. Panda, Priyambada Panda, Mahesh Chandra sahu, ChinmayeeMohapatra. (2015) Morphometric Analysis of the Foramen Magnum and the Occipital condyles. *IJPSRR.* Vol 33.