



## MRI EVALUATION OF DISC HERNIATIONS IN PATIENTS WITH LOW BACK PAIN

## Radiodiagnosis

<b>Dr. Garg Yogesh</b>	Junior resident, Department of Radiodiagnosis, Rajindra Hospital, G.M.C. Patiala
<b>Dr. Mohi Jaswinder Kaur</b>	Associate Professor, Department of Radiodiagnosis, Rajindra hospital, G.M.C. Patiala
<b>Dr. Kaur Navkiran</b>	Professor and Head, Department of Radiodiagnosis
<b>Dr. Rekha</b>	Senior Resident, Department of Radiodiagnosis, AIIMS Jodhpur
<b>Dr. Malik Priyanka*</b>	Senior resident, Department of Biochemistry, Rajindra Hospital, G.M.C. Patiala *Corresponding Author

## ABSTRACT

**Background:** Low back pain (LBP) is one of most common complaints throughout the world and our country due to degenerative spine disorder. In most of the developed countries LBP resulting from the degenerative spine diseases is the most common cause of physical disability in all ages, predominantly in 4th decade and above age groups and second most common cause to seek consultation from physician.

**Aims:** The aim of this study was to assess the role of MRI in the evaluation of disc herniations in patients with low backpain. **Material and Methods:** This cross-sectional study was conducted on forty patients with chief complaint of low back pain

**Results:** Among various types of herniations, asymmetric disc bulge and posterocentral herniation was seen in maximum number of patients. The frequency of disc herniation was seen increasing downwards being maximum at L5-S1 disc level.

**Conclusion:** It was concluded that there is high yield of disc herniation diagnosis with MRI scan among low back pain patients with clinical need for invasive intervention, hence an excellent navigating tool.

## KEYWORDS

low backpain, disc herniation, MRI

## INTRODUCTION

Disc herniation is defined as a localized displacement of nucleus, cartilage, fragmented apophyseal bone, or fragmented annular tissue beyond the intervertebral disc space. A bulging disc is not considered a herniated disc and is defined as the presence of disc tissue diffusely (> 50% of the circumference) extending beyond the edges of the ring apophyses. This bulging can be symmetric or asymmetric. [1] [Fig 1,2]

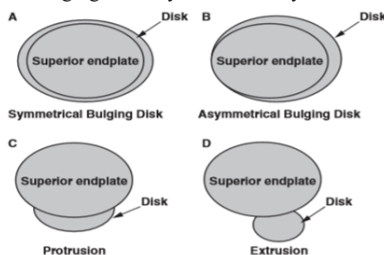


Figure 1

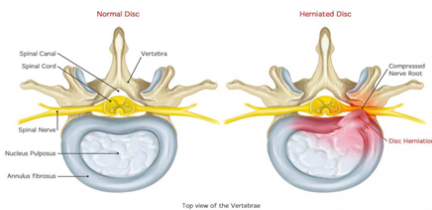


Figure 2

Herniations are subdivided into protrusion and extrusions. **Disc Protrusion** is present if the greatest distance in any plane between the edges of the disc material beyond the disc space is less than the distance between the edges of the base in the same plane. If in any plane the greatest distance between the edges of the disc goes beyond the distance between the edges of the base, the lesion is called "**Extrusion**". [1] [Fig 2,3] In practical terms, if the herniated disc material has a neck, it is an extrusion. T1- and T2-weighted sagittal and axial MR images can clearly visualize the vertebral endplates and intervertebral discs. [2] **Sequestered disc**, also referred to as a free disc fragment, corresponds to extruded disc material that has no continuity with the parent disc and is displaced away from the site of extrusion.

## MATERIALS AND METHODS

This cross-sectional study was carried out on 40 patients with chief complaint of low back pain in Department of Radio diagnosis, Government Medical College, Rajindra Hospital, Patiala which were referred to our department for MRI from the outpatient department and emergency from the Department of orthopedics. A detailed history along with complete clinical examination was done before the MRI examination.

## PATIENT PREPARATION

Before evaluating a patient by MRI imaging informed consent was obtained from the patient or guardian and the procedure was briefly explained to the patient or guardian.

## Inclusion criteria:

1. Patients of age (20-65 years) with chief complaint of low back pain who were referred for MRI to Department of Radiology, Government medical college and Rajindra hospital Patiala.
2. Radicular low back pain radiating to one or both lower limbs.
3. LBP Associated with neurological deficits including bowel and bladder disturbances.
4. LBP with some infective, neoplastic or traumatic history.

## Exclusion criteria:

1. Patients having cardiac pacemakers and electromagnetic implants.
2. Non manageable severe claustrophobia.
3. Age (less than 20 years and more than 65 years)
4. Patient who refused to give consent.

## Study equipment:

- SIEMENS 1.5 TESLA MRI superconducting magnet. Standard surface coils and body coils for lumbar spine for acquisition of images.

## SEQUENCES

- Conventional spin echo sequences T1WI, T2WI, STIR sag, T1WI axial, T2WI axial and post contrast T1 axial, sag and coronal.
- **TECHNIQUE**
- MRI LUMBOSACRAL SPINE was done in all cases on SIEMENS 1.5 TESLA MRI superconducting magnet. Initially non contrast T1 weighted (T1W), T2 weighted (T2W) and short tau inversion recovery (STIR) sequences in axial, sagittal and

coronal planes of the involved spine will be taken. Then post-contrast T1 sequence will be obtained by using intravenous administration of gadodiamide (GdDTPA-BMA) of 0.2 mmol/kg doses, in axial, coronal and sagittal planes in selected cases. Several parameters that were noted on MRI are described in performa.

**STUDY ANALYSIS**

- A total of 40 patients were included in this study. Informed consent was taken from all the subjects before starting the study. After fulfillment of all the inclusion and exclusion criteria, MR imaging of LUMBOSACRAL SPINE was done by various MR techniques by 1.5-T superconductive scanner (Siemens 1.5T Magnetom aera MRI machine).

**RESULTS**

Of the 40 patients evaluated with MRI lumbosacral spine for low backpain, diffuse disc bulge was seen in 9 patients (22.5%), asymmetric disc bulge was seen in 27 patients (67.5%), protrusion, extrusion and sequestration were seen in 2 patients (5%) . Among various types of herniations, asymmetric disc bulge was seen in maximum number of patients. (Table 1)

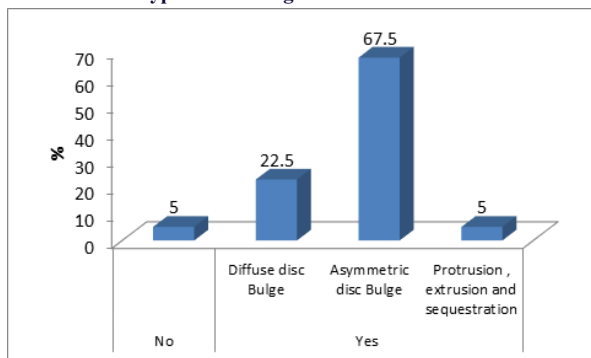
Of the 40 patients evaluated with MRI lumbosacral spine for low backpain, diffuse disc bulge was seen in 9 patients (22.5%), posterocentral herniation was seen in 25 patients (62.5%), paracentral herniation was seen in 6 patients (15%), foraminal herniation was seen in 5 patients (10%) and extraforaminal herniation is seen in 5 patients (12.5%) .Among various types of herniations, posterocentral herniation was seen in maximum number of patients. (Table 2)

Disc herniation was seen in 6 patients (6.4%) at L1-L2 level, in 8 patients (8.6%) at L2-L3 level, in 21 patients (22.5%) at L3-L4 level, in 27 patients (29.0%) at L4-L5 level and in 31 patients (33.3%) at L5-S1 level. The frequency of disc herniation was seen increasing downwards being maximum at L5-S1 disc level.(Table 3)

**Table 1: Distribution of types of disc bulge and herniations**

Types of disc bulge and herniations		Number of patients	Percentage
No		2	5.0
Yes		38	
Yes	Diffuse disc Bulge	9	22.5
	Asymmetric disc Bulge	27	67.5
	Protrusion , extrusion and sequestration	2	5
Total		40	100.0

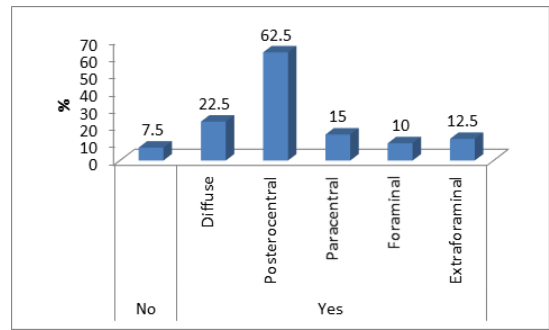
**Distribution of types of disc bulge and herniations**



**Table 2: Location wise distribution of disc herniations**

		Number of patients	Percentage
No		3	7.5
Yes		37	
Yes	Diffuse	9	22.5
	Posterocentral	25	62.5
	Paracentral	6	15
	Foraminal	4	10
	Extraforaminal	5	12.5
	Total	40	100.0

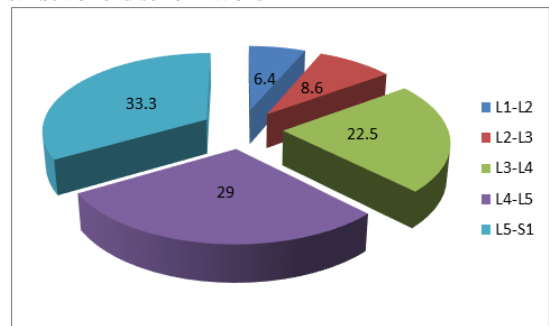
**Location wise distribution of disc herniations**



**Table 3: Distribution of disc herniations**

Disc Levels	Number of herniations	Percentage
L <sub>1</sub> -L <sub>2</sub>	6	6.4
L <sub>2</sub> -L <sub>3</sub>	8	8.6
L <sub>3</sub> -L <sub>4</sub>	21	22.5
L <sub>4</sub> -L <sub>5</sub>	27	29.0
L <sub>5</sub> -S <sub>1</sub>	31	33.3

**Distribution of disc herniations**



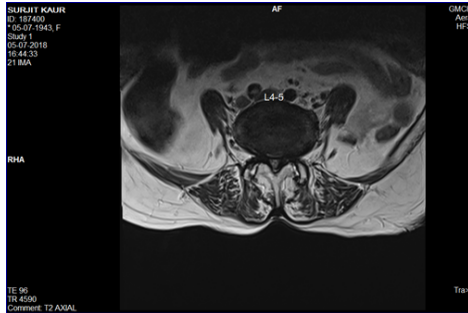
**DISCUSSION**

In the present study, out of 40 patients evaluated with MRI lumbosacral spine for low backpain, diffuse disc bulge was seen in 9 patients (22.5%), asymmetric disc bulge was seen in 27 patients (67.5%), protrusion, extrusion and sequestration were seen in 2 patients (5%) . Among various types of herniations asymmetric disc bulge was seen in maximum number of patients. In a study conducted by Rohini et al<sup>[1]</sup> (2017) ,disc bulge was seen in 78.6% of patients while disc herniations were seen in 43.3% of patients and most profoundly affecting L4-L5 disc level. In another study conducted by Kohat et al<sup>[4]</sup> (2017) similar results were found. Diffuse annular disc bulge was seen in 69.4% patients, disc protrusion in 48.6% patients, extrusion in 19.4% of patients and sequestered disc in 1 out of 72 patients. In another study conducted by Idiboyi et al<sup>[5]</sup> (2018), ninety Percent of the patients have disc bulge; while 63.3% fall within the spectrum of disc bulge to herniation, about 26.7% fall within the spectrum from disc extrusion to sequestration.

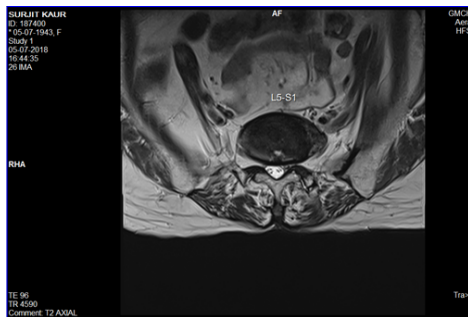
Of the 40 patients evaluated with MRI lumbosacral spine for low backpain, diffuse disc bulge was seen in 9 patients (22.5%), posterocentral herniation was seen in 25 patients (62.5%), paracentral herniation was seen in 6 patients (15%), foraminal herniation was seen in 5 patients (10%) and extraforaminal herniation is seen in 5 patients (12.5%). Among various types of herniations, posterocentral herniation was seen in maximum number of patients. Rai GS et al<sup>[6]</sup> (2016) observed that posterocentral disc protrusion was most common (83%) followed by posterolateral type (9%) which is in concordance with our study. In another study performed by Sathish Babu et al<sup>[7]</sup> (2017) a total of 500 discs were observed. It showed the location of herniation in a degenerative disc disease, posterolateral disc bulge was most common location seen. Maximum number was posterolateral (right central and left central) (224) followed by central (88) and foraminal (58).

Disc herniation was seen in 6 patients (6.4%) at L1-L2 level, in 8 patients (8.6%) at L2-L3 level, in 21 patients (22.5%) at L3-L4 level, in 27 patients (29.0%) at L4-L5 level and in 31 patients (33.3%) at L5-S1 level. The frequency of disc herniation was seen increasing downwards being maximum at L5-S1 disc level. In a study conducted by Erhler Marco et al (2016). Fifty percent of lumbar disc herniations

were at the L5/S1 level and the majority of herniations were paracentral in location. In a study conducted by Evrin Ekin et al<sup>[8]</sup> (2018), disc degeneration was observed in 66% of all patients. In the evaluation based on intervertebral disc level, the most frequent disc degeneration was observed at L5 - S1 and L4 - L5, while the least frequent disc degeneration was observed at L2 - L3 and L1 - L2 levels, respectively. Another study conducted by Rai GS et al<sup>[6]</sup> (2016) showed 30 cases (30%) in the study with posterior disc bulge; 28 of them had diffuse posterocentral bulge and 2 of them had posterolateral bulge. Most of the cases show disc bulge at L4-L5 and L5-S1 level accounting total 21 cases. Most commonly involved level in protrusion cases was L5-S1 (8 cases) then involving L4-L5 (7 cases).



**Figure (A) T2 AXIAL Image shows asymmetric diffuse disc bulge with posterocentral herniation causing compression of thecal sac and compression of bilateral traversing nerve roots at L4-L5 disc level.**



**Figure (B) T2 AXIAL Image shows diffuse disc bulge with posterocentral herniation causing indentation of thecal sac and impingement of left traversing nerve root. An annular tear is seen along the posterior aspect of the L5-S1 disc.**

## CONCLUSION

Based on the results of our study the following conclusions can be made: Of the 40 patients evaluated with MRI lumbosacral spine for low backpain, diffuse disc bulge was seen in 9 patients (22.5%), asymmetric disc bulge was seen in 27 patients (67.5%), protrusion, extrusion and sequestration were seen in 2 patients (5%). So asymmetric disc bulge was seen in maximum number of patients.

Of the 40 patients evaluated with MRI lumbosacral spine for low backpain, posterocentral herniation was seen in 25 patients (62.5%), paracentral herniation was seen in 6 patients (15%), foraminal herniation was seen in 5 patients (10%) and extraforaminal herniation is seen in 5 patients (12.5%). Among various types of herniations, posterocentral herniation was seen in maximum number of patients.

Disc herniation was seen in 6 patients (6.4%) at L1-L2 level, in 8 patients (8.6%) at L2-L3 level, in 21 patients (22.5%) at L3-L4 level, in 27 patients (29.0%) at L4-L5 level and in 31 patients (33.3%) at L5-S1 level. The frequency of disc herniation was seen increasing downwards being maximum at L5-S1 disc level.

There is high yield of diagnosis with MRI scan among low back pain patients with clinical need for invasive intervention, hence an excellent navigating tool.

Magnetic Resonance Imaging (MRI) was able to detect the morphological abnormalities due to its excellent spatial resolution, high soft tissue contrast and its multiaxial, multiplanar abilities. These inferences would help improve the understanding of MRI of the

lumbar spine in low back pain and thus enhance greatly the management of the patients.

## REFERENCES

1. Fardon DF, Milette PC. Nomenclature and classification of lumbar disc pathology: recommendations of the Combined Task Forces of the North American Spine Society, American Society of Spine Radiology, and American Society of Neuroradiology. *Spine* 2001; 26:E93-E113
2. Beattie PF. Current understanding of lumbar intervertebral disc degeneration: a review with emphasis upon etiology, pathophysiology, and lumbar magnetic resonance imaging findings. *J Orthop Sports Phys Ther* 2008; 38:329-40
3. Singh R, Hazra I, Ahmad S. Spectrum of magnetic resonance imaging findings in patients of low back pain at a tertiary care institute of West Bengal. *Int J Med Sci Public Health* 2017;6(9):1421-6.
4. Kohat AK, Kalita J, Ramanivas S, Misra UK, Phadke RV. Clinical significance of magnetic resonance imaging findings in chronic low backache. *The Indian journal of medical research.* 2017 Jun;145(6):796.
5. Iyidobi EC, Obande BO, Ekwunife RT. Pattern of MRI Findings in Patients with Low Back Pain at National Orthopaedic Hospital, Enugu Nigeria. *Journal of Biosciences and Medicines.* 2018 Apr 4;6(04):85.
6. Rai GS, Mehra A, Gaur TN. A prospective study of magnetic resonance imaging findings in patients of chronic low back pain: a clinico-radiological correlation. *International Journal of Research in Medical Sciences.* 2016 Jan;4(1):47.
7. SathiSh BaBu S, Vinod S, anu Priya Jt. Application of MRI in the Evaluation of Low Backpain. *International Journal of Anatomy, Radiology and Surgery.* 2017 Apr, Vol-6(2):RO37-40.
8. Ekin EE, Altunrende ME. Chronic Low Back Pain in Young Population: An MRI Study. *Middle East Journal of Rehabilitation and Health.* 2018 Apr;5(2).