



## POST RADIATION ANGIOSARCOMA IN THE ERA OF BREAST CONSERVING SURGERY FOR CARCINOMA BREAST.

### Pathology

<b>Meenakshi Swain*</b>	Senior Consultant, Department of Pathology, Apollo Hospitals, Jubilee Hills, Hyderabad – 500 096, Andhra Pradesh *Corresponding Author
<b>Manal Ahmed</b>	Department of Pathology, Apollo Hospitals, Jubilee Hills, Hyderabad – 500 096, Andhra Pradesh
<b>Gowrishankar Swarnalata</b>	Department of Pathology, Apollo Hospitals, Jubilee Hills, Hyderabad – 500 096, Andhra Pradesh
<b>Bhandari TPS</b>	Dept. of Surgical Oncology, Apollo Hospitals, Jubilee Hills, Hyderabad – 500 096, Andhra Pradesh

### ABSTRACT

Angiosarcomas comprise only 1% of all sarcomas, of which 60% occur in the skin or soft tissue. Angiosarcoma in the breast is rare, accounting for less than 1% of all malignant mammary lesions. These may be of primary/de novo type in the breast parenchyma or secondary following surgery and radiotherapy. We report a case of post radiation angiosarcoma of the breast, developing 4 years after breast conservation surgery for an invasive duct carcinoma. Following excision of angiosarcomas, local recurrence is common and course aggressive, thus making essential a quick and correct diagnosis and close follow up of such cases.

### KEYWORDS

Angiosarcoma, breast, post- radiation

### INTRODUCTION:

Angiosarcomas comprise 2% of all sarcomas, of which 60% occur in the skin or soft tissue<sup>1</sup>. Mammary angiosarcomas can be primary in breast parenchyma or a secondary type of skin and underlying soft tissue following radical mastectomy and radiotherapy or after breast conserving surgery and radiotherapy. Chronic lymphedema is the most widely recognized predisposing factor for angiosarcomas. The presentation and behavior of these tumours differ depending upon location and are divided into several clinical groups namely: subcutaneous angiosarcomas not associated with lymphedema, cutaneous angiosarcomas associated with chronic lymphedema, angiosarcomas of the breast, radiation induced angiosarcomas and angiosarcomas of the soft tissue<sup>2</sup>. Here, we discuss a case of post radiation angiosarcoma of the breast, developing 4 years after breast conserving surgery for a low grade, invasive duct carcinoma, followed by radiation therapy.

### CASE SUMMARY:

A 66 year old lady presented with a grey brown nodule on the skin of her right breast. She was a known case of invasive duct carcinoma of right breast, with no axillary lymphnode metastasis and had undergone breast conserving surgery 4½ years ago in another hospital. This was followed by radiotherapy and chemotherapy, following which her recovery was uneventful. 4 years later she presented with a grey brown nodule on the skin of her right breast. Clinically a recurrence of duct carcinoma was suspected and the lesion biopsied. The histology was reported as a recurrent duct carcinoma elsewhere and these slides were reviewed at our hospital and reported as an angiosarcoma. She underwent a modified radical mastectomy. On gross examination, the specimen measured 23 x 17 x 6 cm with overlying skin measuring 14 x 9 cm. The skin showed a healed surgical scar, possibly corresponding to the site of previous surgery. At a distance of 4 cm from the scar was a grey brown nodule measuring 1.5 x 1 cm (Fig. 1). Other nodules were smaller and cut surface was grey brown, rest of the breast parenchyma showed fibrotic, grey white and haemorrhagic areas.

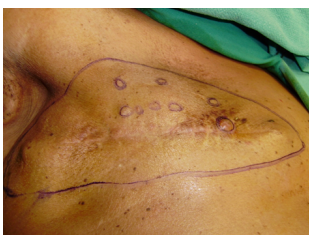

Figure- 1 Nodules on the skin of breast adjacent to the previous surgical scar.

On light microscopy, sections from the grey brown nodules and the area below the scar showed a neoplastic lesion. The lesion was composed predominantly of solid sheets and slit like spaces lined by plump ovoid to spindle cells with hyperchromatic nuclei having coarse chromatin and prominent nucleoli. In few areas the tumour cells were seen lining spaces filled with red blood cells (Fig 2). Brisk mitosis and foci of necrosis were evident. The overlying epidermis was unremarkable and there was no evidence of an invasive duct carcinoma. On immunohistochemistry, the tumour cells were negative for pancytokeratin, ER, PR and Her-2 neu. They were positive for CD31, CD34 and vimentin (Fig 3).

A final diagnosis of a high grade angiosarcoma was made. The slides of the wide excision of the right breast lump done 4 years ago were reviewed and confirmed as a grade I, invasive duct carcinoma with no evidence of metastasis in the lymph nodes (Fig 4).

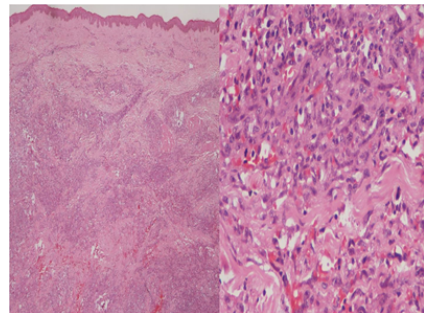


Figure 2 Phot micrograph showing skin of breast with underlying neoplastic proliferation of cells.( Left panel, H&E, 10X). The tumor cells are arranged in sheets, with slit like spaces lined by plump ovoid to spindle cells with hyper chromatic nuclei.( Right panel, H&E, 40X)

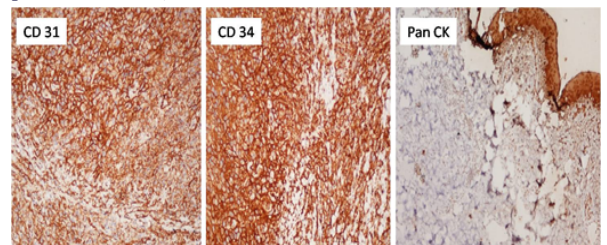
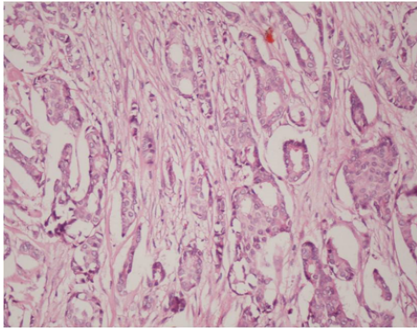


Figure-3 The tumour cells are strongly positive for CD31,CD34 and negative for Pancytokeratin.(40X)



**Figure-4 Grade I, Invasive duct carcinoma in the initial lumpectomy specimen. (H&E,40X)**

#### DISCUSSION:

Primary angiosarcoma of the breast is a rare tumour, accounting for 0.05% of primary malignancies of the breast<sup>3</sup>. Secondary angiosarcomas in the breast usually develop 3-12 years after primary radiotherapy with a mean interval being approximately 6 years<sup>4</sup>. Stewart Treves iatrogenic angiosarcoma (STAS) is attributed to chronic lymphedema<sup>5</sup>. Recently a new form of cutaneous post irradiation angiosarcoma of the breast (CPRASB) related to breast conserving therapy has been recognized which differs from STAS by a shorter latency period and absence of chronic lymphedema<sup>6</sup>. Patients with CPRASB are typically women with limited stage breast disease (pT1, pT2) who have received lumpectomy and lymph node dissection. CPRASB contrasts with STAS in which lymphedema is not only definitional but extensive and usually of long duration.<sup>7,8,9</sup>

The reason for this short interval for the development of CPRASB is unclear. The overall dosing and fractionation are not significantly different from that used in other adjuvant radiation therapy protocols.

One possibility includes the volume of skin irradiated. The entire skin of breast is treated, as dermal recurrences of mammary carcinoma are well known<sup>6</sup>. Alternatively, the short interval may represent an unusual phenomenon unique to breast tissue. A third possibility is that there is synergism between radiation and adjuvant chemotherapy.<sup>6</sup>

Patients with invasive carcinomas are at a risk of developing angiosarcoma as a complication, with radiation becoming essential with breast conserving therapy. Delays in the diagnosis of secondary angiosarcomas may be due to the fact that they are clinically subtle. The clinical presentation varies from skin thickening or discoloration which is mistaken for post radiation morphea. They could also mimic inflammation, trauma or malignant melanoma<sup>10</sup>. Like STAS, CPRASB is typically a multifocal, erythematous or violaceous lesion but, unlike STAS, is consistently located within the radiation field<sup>6</sup>.

Besides a high degree of clinical suspicion, unless appropriate diagnostic methods are used the lesion may be overlooked. Sonography is useful. Diffuse, abnormal, mixed hyperechogenic and hypoechogenic regions without a discrete mass might be noted<sup>11</sup>.

Therefore, biopsy with appropriate immune stains is considered the gold standard for correct diagnosis, since these tumours are aggressive, with a fulminant course. Three grades of angiosarcomas are described. The low grade tumour consists of anastomosing vascular channels which invade surrounding breast tissue. Intermediate grade have more solid neoplastic vascular growth and an increased mitotic rate. High grade have in addition frankly sarcomatous areas as well as areas of necrosis, haemorrhage and infarction.

As more experience is gained with CPRASB, a larger issue is raised. Does the risk of post radiation induced angiosarcomas outweigh the benefits of radiation therapy? Current data suggest that the risk of CPRASB does not outweigh the potential benefit of adjuvant radiation therapy<sup>6</sup>.

The prognosis of secondary angiosarcoma is poor as most patients develop hematogenous metastasis. Our patient died 3½ years after diagnosis. With breast conserving surgery becoming a popular modality for treatment, we are likely to see more cases of secondary angiosarcoma. Hence, awareness of the entity and an appropriate panel of immuno histo chemical stains could help make the right diagnosis.

#### REFERENCES:

1. Mark RJ, Poen JC, Tran LM, Fu YS, Julliard GF. Angiosarcoma- A report of 67 patients and a review of literature. *Cancer* 1996; 77(11):2400-6.
2. Enzinger F, Weiss S, Goldblum J. *Soft Tissue Tumors*. 5th ed. China: Mosby; 2008
3. Nascimento AF, Raut CP, Fletcher CD: Primary angiosarcoma of the breast: Clinicopathological analysis of 49 cases, suggesting that grade is not prognostic. *Am J Surg Pathol* 2008 Dec; 32(12):1896-904.
4. Rao J, Dekoven JG, Beatty JD, Jones G. Cutaneous angiosarcoma as delayed complication or radiation therapy for carcinoma of the breast. *J. Am Acad Dermatol* 2003; 49: 532-8.
5. Tavassoli FA, Devilee P, editors. *WHO Classification of tumours, pathology and genetics, tumour of the breast and female genital organs*. 4th ed. Lyon: WHO press; 2003.
6. Billings S, Mckenny JK, Folpe AL, Hardacre MC, Weiss SW. Cutaneous angiosarcoma following breast conserving surgery and radiation : an analysis of 27 cases. *Am J Surg Pathol* 2004; 28:781-8.
7. Sordello PP, Chapman R, Hajdu S I, et al. Lymphangiosarcoma. *Cancer* 1961; 48:1674-1679.
8. Stewart F W, Treves N. Lymphangiosarcoma in post mastectomy lymphedema; a report of 6 cases in elephantiasis. *Chirurg Cancer* 1948; 1:64-81.
9. Woodward A H, Ivins I C, Soule E H. Lymphangiosarcoma arising in chronic lymphedematous extremities. *Cancer* 1972; 30:562-572.
10. Cafiero F, Gipponi M, Peressini A, et al . Radiation associated angiosarcoma; diagnostic and therapeutic implications two case reports and a review of the literature. *Cancer* 1996; 77: 2496-502.
11. Soama AS, Anwar AM. Angiosarcoma of the breast: A case report. *Journal of the Royal Medical Services* 2011 March; 18(1): 71-75.