



## EPIDEMIOLOGY, PRESENTATION AND PATHOLOGICAL FINDINGS OF RETROPERITONEAL TUMORS, AND LITERATURE REVIEW

### Surgery

<b>Lokesh Arora</b>	MBBS, DNB, Sri venkateswara institute of medical sciences, Tirupati
<b>Musunuru Brahmeswara Rao*</b>	MBBS, MS, MCH, Sri venkateswara institute of medical sciences, Tirupati *Corresponding Author
<b>Vutukuru Venkatarami Reddy</b>	MBBS, MS, DNB, Sri venkateswara institute of medical sciences, Tirupati
<b>Chandrakasan Chandra maliteeswaran</b>	MBBS, MS, DNB, Sri venkateswara institute of medical sciences, Tirupati

### ABSTRACT

**INTRODUCTION:** In this retrospective study, our aim is to study epidemiology of retroperitoneal tumors and correlate clinical presentation of patients with radiological and final pathological findings.

**METHODS:** All the patients with the diagnosis of retroperitoneal tumor are included. Known Lymphoma or the patients with enlarged peripheral lymph nodes and metastatic tumors are excluded.

**RESULTS:** Total of 27 patients presented with retroperitoneal tumors. Mean age at presentation was 48.07±13.40. 17(62.96%) out of 27 patients were females. Most common presentation was (18, 66.7%) Pain abdomen, followed by lump abdomen (11,40.7%). Most common tumor in our series is sarcoma, (14.8%).

**CONCLUSION:** In our analysis of 27 patients, Retroperitoneal tumors are found predominantly in females in 5th decade of life. Majority of the patients presented with non specific pain abdomen. Radiological assessment is key to diagnosis, with CT scan playing a major role in preoperative diagnosis.

### KEYWORDS

Retroperitoneal tumor, adreno cortical carcinoma, chylolymphatic cyst, dysgerminoma, gist, leiomyosarcoma, liposarcoma, malignant fibrous histiocytoma, mullerian cyst, neuroendocrine tumor, pheochromocytoma

### INTRODUCTION

Primary retroperitoneal neoplasms include uncommon tumors that emerge inside the retroperitoneum yet, outside the retroperitoneal organs.<sup>1</sup>

The retroperitoneum can have a wide range of pathologies, including benign and malignant neoplasms that can be either primary or metastatic. Out of which, malignant tumors are more common, and sarcomas are commonest malignant tumor of retroperitoneum.<sup>2</sup>

While the retroperitoneum is certainly not a genuine anatomic compartment. muscle sheaths posteriorly, adventitia of great vessels medially and the peritoneum itself anteriorly can be considered as boundaries.<sup>3</sup>

Anatomy: the retroperitoneum is extended anteriorly to peritoneal extensions anchoring the colon, small bowel, duodenum, part of pancreas and liver, extending from the diaphragm to the pelvic floor. The floor of the space is formed by the fascia overlying the quadratus lumborum and psoas major muscles.<sup>4</sup>

Because of the inaccessibility of the region and since these tumors regularly give no or non-specific manifestations until they have achieved a generous size, they are typically large at presentation.<sup>2</sup>

In this retrospective study, we studied patients presented with retroperitoneal mass at presentation, radiological findings and pathological specimens were reviewed and correlated with clinical findings.

### MATERIALS AND METHODS

Aim is to study epidemiology of retroperitoneal tumors and correlate clinical presentation of patients with radiological and final pathological findings.

It is a single center retrospective study from jan 2015 to dec 2018.

All the patients who were admitted in SVIMS Gastroenterology department with the diagnosis of retroperitoneal tumor were included in study.

Patients with known Lymphoma or the patients with enlarged peripheral lymph nodes are excluded from the study. Metastatic tumors, patients with known primary or in whom pathological diagnosis is metastatic deposits with unknown primary are also excluded from study

### CLINICAL PRESENTATION

Total of 27 patients presented with retroperitoneal tumors. Mean age at presentation was 48.07±13.40, minimum age was 20 while maximum age at presentation was 75 years

Seventeen (62.96%) out of 27 patients were females.

Most of the patients (18, 66.7%) presented with Pain abdomen, second most common symptom at presentation was lump abdomen (11,40.7%). Three patients (11.1%) were asymptomatic and diagnosis was made incidentally.

Majority of patients were not having any comorbidities, with 4 patients (14.8%) being diabetic and 2 patients (7.4%) hypertensive. No other major illness was present in any of the 27 patients.

There is no significant correlation with alcoholism and tobacco use. In only 3 patients smoking and alcohol history is present.

Out of 27 patients, 11(40.7%) were diagnosed on ultrasound and later confirmed with cross sectional imaging and 19 patients (70.4%) were diagnosed on cross sectional imaging.

**Table 1: Retroperitoneal tumors, pathological results and their frequency**

	Frequency	Percent
LOST TO FOLLOW UP	1	3.7
ABSCESS	2	7.4
ADRENO CORTICAL CARCINOMA	2	7.4
CHYLOLYMPHATIC CYST	3	11.1
DYSGERMINOMA	1	3.7
GIST	5	18.5
LEIOMYOSARCOMA	4	14.8

LIPOSARCOMA	3	11.1
MALIGNANT FIBROUS HISTIOCYTOMA	2	7.4
MULLERIAN CYST	1	3.7
NEUROENDOCRINE TUMOR	1	3.7
PHEOCHROMOCYTOMA	2	7.4
Total	27	100.0

Most common tumor in our series is sarcoma, (14.8%) leiomyosarcoma and 11.1% liposarcoma and one patient malignant fibrous histiocytoma. Five patients (18.5%) were diagnosed with retroperitoneal GIST. One patient in our series was lost to follow up.

## DISCUSSION

Primary retroperitoneal tumor is uncommon diagnosis. Their overlapping clinical presentation and radiological appearance pose a diagnostic challenge. This single centre study examined the clinical presentation of retroperitoneal tumors and compared with radiological and postoperative pathological findings.

## SARCOMA

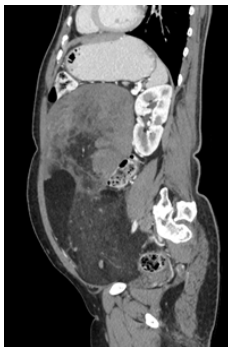
Of all sarcomas, the majority occur outside of the retroperitoneum. Retroperitoneal sarcoma is a rare disease accounting for 0.1-0.2% of all malignancies. Only 10%–20% of sarcomas are retroperitoneal sarcomas. But sarcomas represent 33% of all retroperitoneal tumors. Most common primary malignant tumors of retroperitoneum are sarcomas. The most common histologic subtypes are liposarcoma and leiomyosarcoma. There is no predominance in terms of gender. Our study has female predominance, out of 8 sarcomas, 6 are females.<sup>5,6,7</sup> These tumors can be found anywhere in the body, with half in the extremities.

## LEIOMYOSARCOMA

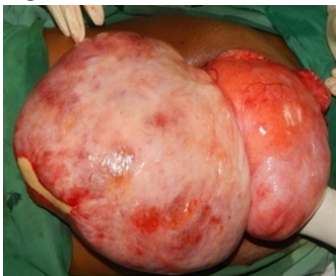As leiomyosarcoma derived from smooth muscle cells, its rare in retroperitoneum, but the most common retroperitoneal sarcoma is leiomyosarcoma.<sup>5,6,7</sup> In our study the average age of patients was 54.5 years old (the ratio of males to females was 1:3); common clinical presentations were abdominal pain, abdominal lump. In 3 out of 4 cases CT scan was able to diagnose solid retroperitoneal tumor.

## LIPOSARCOMA

The average age of patients was 49.67 years old (the ratio of males to females was 0:3); common clinical presentations were vague abdominal pain and abdominal distension. CT scan was diagnostic in all cases as solid retroperitoneal tumors. Out of the three operated cases, two were recurrent tumors, operated elsewhere and referred for recurrence.<sup>5,6,7</sup>



**Figure 1: Large retroperitoneal tumor, mixed density lesion into abdomen with soft tissue component and fat attenuating component -s/o liposarcoma.**



**Figure 2: Large liposarcoma, arising from retroperitoneum and filling complete abdomen**

## MALIGNANT FIBROUS HISTIOCYTOMA

Malignant fibrous histiocytomas arise from primitive mesenchymal elements, most commonly in extremities followed by abdomen and retroperitoneum. In our series only one male patient presented with malignant fibrous histiocytoma. Age of the presentation was 53 years. Patient had recurrence for which he was re-operated 5 months after primary surgery. CT scan was suggestive of retroperitoneal soft tissue density lesion.<sup>5,6,7</sup>

## GASTROINTESTINAL STROMAL TUMORS (GIST)

The GISTs are the most common mesenchymal tumors of the gastrointestinal tract, rarely GIST may arise outside gastrointestinal tract. GIST arising in retroperitoneum is extremely rare and aggressive. It is hypothesized that these tumors originate from common precursor cells which differentiate into the Interstitial Cells of Cajal (precursor cell of GIST) type outside from the gut wall. We encountered 5 retroperitoneal GIST in our series. Mean age of presentation was 47.4 years. Slightly male predisposition with male to female ratio was 3:2. Most common presentation was abdominal lump with dull aching pain abdomen. CT scan was diagnostic in all cases.<sup>5,6,7,8</sup>

## RETROPERITONEAL CYST

Retroperitoneal cysts are grouped into (a): Urogenital; (b): Mesocolic; (c): Cysts emerging in cell considerations; (d): Traumatic; (e): Parasitic and (f): Lymphatic. In our series 4 patients presented with primary cystic lesions in retroperitoneum. Three patients were diagnosed as chylolymphatic cysts on final pathological examinations, while one was mullerian cyst. Urogenital cysts emerge from the remnants of the embryonic urogenital rests and can be divided into pronephric, mesonephric, metanephric, and mullerian. While chylolymphatic cysts are unilocular or multilocular cysts containing clear or milky fluid and lined with a single layer of endothelium. These patients were comparatively younger than malignant tumors, average age of presentation was 34.75 years. All four patients were females. And CT scan was able to diagnose a cystic lesion in retroperitoneum in all four cases.<sup>9</sup>

## MALIGNANT GERM CELL TUMOR

Extragenital germ cell tumor represents 5–10% of germ cell tumors and frequently occurs in mediastinum, retroperitoneum, pineal gland, or sacral area. They are mostly benign, such as teratoma and yolk sac tumor. Typical malignant Extragenital germ cell tumors mainly include malignant teratoma and embryonal carcinoma, while seminoma and choriocarcinoma are rarely seen.<sup>10</sup> One patient of malignant germ cell tumor i.e. dysgerminoma presented as retroperitoneal mass. Primary extragenital germ cell tumors are thought to arise from primordial germ cells that remain ectopic. Our patient was a 40 year old male, presented with nonspecific pain abdomen. CT scan was suggestive of retroperitoneal mass? GIST.

## OTHERS

One patient of neuroendocrine tumor, two chronic abscesses, out of which one appendicular were among other tumors. Three were adrenal tumors, out of which one patient was of adreno-cortical carcinoma and other two were pheochromocytoma.

## CONCLUSION

In our analysis of 27 patients, Retroperitoneal tumors are found predominantly in females in 5<sup>th</sup> decade of life. Majority of the patients presented with non specific pain abdomen. Radiological assessment is key to diagnosis, with CT scan playing a major role in preoperative diagnosis. Histopathology is the final key to diagnosis and further treatment.

## REFERENCES

- Füllhase C, Harke N, Niedworok C, Protzel C, Hakenberg OW. Retroperitoneal Tumors in Adults. *Urologic Oncology*. 2019;1-4.
- Çalışkan M, Evren İ, Acar A, Ekşi M. Analysis of Cases with Primary Retroperitoneal Tumors. *Medical Journal of Bakirkoy*. 2019 Mar 1;15(1).
- Fiore M, Sandrucci S. Current Principles of Surgical Management of Retroperitoneal Sarcomas. In *Current Treatment of Retroperitoneal Sarcomas 2019* (pp. 49-60). Springer, Milano.
- Lambert G, Samra NS. Anatomy, Abdomen and Pelvis, Retroperitoneum. In *StatPearls [Internet]* 2019 Oct 27. StatPearls Publishing.
- Quagliuolo V, Ruspi L, Cananzi FC, Gronchi A. History of Surgery in Retroperitoneal Sarcomas. In *Current Treatment of Retroperitoneal Sarcomas 2019* (pp. 1-7). Springer, Milano.
- Adam MA, Moris D, Behren S, Nussbaum D, Jawitz O, Turner M, Lidsky M, BLAZER D. Hospital Volume Threshold for the Treatment of Retroperitoneal Sarcoma. *Anticancer Research*. 2019 Apr 1;39(4):2007-14.
- Balzarini L, Gennaro N, Morosi C. Imaging of Retroperitoneal Sarcomas. In *Current Treatment of Retroperitoneal Sarcomas 2019* (pp. 33-48). Springer, Milano.
- Costa AC, Caroco TV, Albano M, Carvalho L. Extragastrintestinal stromal tumour

- (EGIST) presented as a mesenteric and retroperitoneal mass. *BMJ case reports*. 2019 Dec 2;12(12).
9. Yang DM, Jung DH, Kim H, Kang JH, Kim SH, Kim JH, Hwang HY. Retroperitoneal cystic masses: CT, clinical, and pathologic findings and literature review. *Radiographics*. 2004 Sep;24(5):1353-65.
  10. Luo CH, Chen X, Miao C. Retroperitoneal Extragonadal Germ Cell Tumors. In *Retroperitoneal Tumors 2018* (pp. 253-254). Springer, Dordrecht.