



DELAYED PRIMARY CLOSURE OF THE WOUND IN APPENDICULAR PERFORATION

Dr. M. Ananthan

Assistant Professor , Department of Paediatric surgery, Institute of Child Health and Hospital for Children.Madras Medical College,Chennai, India.

ABSTRACT Despite the routine use of antibiotics that target both aerobic and anaerobic organisms, post appendectomy wound infection is the most common cause of morbidity. It can result in increased pain and a lengthy hospital stay and sometimes major fascial dehiscence leading to bowel prolapse. The rate of wound infection in appendicitis varies from <10% in patients with non-perforated appendicitis to 20% in perforated appendicitis and is highest with diffuse peritonitis (35%). Traditionally, in an effort to decrease the risk of operative site infection, gangrenous or perforated appendicitis has been managed with delayed primary closure. The problem with this method is the requirement of anaesthesia during the procedure. To avoid the second anaesthesia and the requirement of the dissection in the subcutaneous plane for easy closure, we have devised a method.

KEYWORDS : Delayed primary closure , Novel method.

MATERIALS AND METHODS

Our hospital is a tertiary care centre and one of the largest paediatric hospitals in Asia. As it is a Government hospital it caters to the needs of lower middle class and poor socioeconomic groups.

The peculiarity about these groups are high intake of meat products or milk which leads to fecolith formation and high incidence of appendicitis.

1. Both the parents are usually working and the children are often looked after by elderly parents or the neighbours.
2. High levels of illiteracy. Which lead to late presentation of cases with perforative peritonitis.

At ICH, the details of the patients admitted in our unit during the period of 01 January 2016 to 31 December 2018 were taken out and studied. Totally 40 patients were treated in our unit, during that period.

Males	Females
23	17

Age wise, the patients were segregated into the following groups.

Age groups	Less than 3 years	3 to less than 6 years	6 to less than 9 years	9 to 12 years
Number of patients	1	6	12	21

All the patients presented three days after the development of symptoms and were treated either at the clinics or admitted at small hospitals. All of the patients were having perforated appendices along with the formation of foul smelling pus. The quantity of the pus varied between 20 to 50 millilitres.

The laparotomy was done through infra umbilical transverse muscle cutting incision. After the removal of perforated appendix, the entire small bowel was eviscerated and through peritoneal lavage was done with about 2.5 litres of lukewarm normal saline including the sub diaphragmatic areas. The peritoneal lavage fluid was sucked out and the residual fluid was mopped out by the use of the abdominal pads. The myofascial layer was closed with vicryl using the modified smead jones technique.

The skin including the subcutaneous tissue was sutured with 3 zero proline using the vertical mattress technique. The sutures were tied after making a loop of about 15 centimetres. By this method the skin and subcutaneous wounds were left open.

Povidone iodine soaked gauze was inserted into the wound gap and changed twice a day. After 5 days of the dressing like this, the proline knots were tied. The wound healed without any untoward complications.

The dressing changes were done in an aseptic manner and patients tolerated them very well as there was little pain. There was no incidence of any burst abdomen. The patients were discharged on the sixth post operative day.

The follow up was done routinely and revealed nice healing of the skin wound.

DISCUSSION

Wounds are now categorized into clean (no viscus opened), clean-contaminated (viscus opened, minimal spillage), contaminated (viscus opened with spillage or presence of inflammatory disease), and dirty (pus or perforation present or incision made through an abscess).

This categorization was based on a theoretical division of potential for SSI development. It is flawed by the failure to include patient risk and the use of prosthetic materials, which may dramatically impact the risk for SSI in procedures within the clean category. Furthermore, because of the constant introduction of new operative techniques, particularly endoscopic procedures and the rise of natural orifice transluminal endoscopic surgery (NOTES) this categorization is becoming increasingly blurred and may not be applicable. It is critical that standard definitions are used to allow studies to be comparable. The Centers for Disease Control and Prevention (CDC) classification is the most widely used and comprehensive definition.

SSIs are categorized at 3 levels:-

1. Superficial incisional, in the skin or subcutaneous tissues.
2. Deep incisional involving fascia or muscle.
3. deep/organ space, involving, for example, the pleura after lung surgery or the liver after hepatic resection.

Most SSIs fall into the superficial group and the less common deep/organ space infections are the most serious or life threatening.

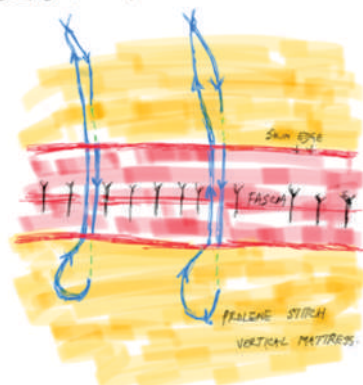
Chiang et al. has reported that the presence of appendiceal perforation is the most important factor associated with the development of postoperative wound infection. They have concluded that in the presence of perforation, wounds should be left open to avoid an increased likelihood of wound infection and longer hospital stay. (1)

In patients with perforated appendicitis with the use of antibiotics the mean length of hospital stay and the mean frequency of change of dressings were significantly reduced (2)

In another study, the management followed a strict protocol with single dose metronidazole as preoperative antibiotic prophylaxis and liberal open wound treatment in case of gross contamination. Consequently, the subcutaneous tissues and the skin were left open in 218 patients. The overall wound infection rate (1.3%) and the intra-abdominal abscess rate (1.1%) were extremely low. Open wound treatment was well accepted by the patients, did not prolong the hospital stay and gave good cosmetic results. (3)

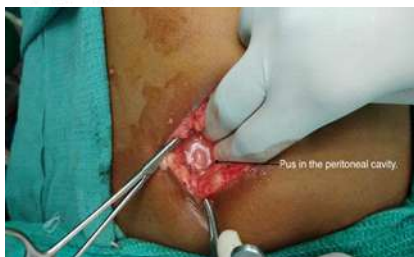In another study, the authors found that preoperative local infiltration of metronidazole into the muscle tissue resulted in a significant reduction in the incidence of infection at the incision site following appendectomy for acute appendicitis. They attribute much of this effect to the direct exposure of anaerobic bacteria to an appropriate antimicrobial medication in areas of limited perfusion. (4)

DELAYED PRIMARY SUTURING OF THE SKIN.

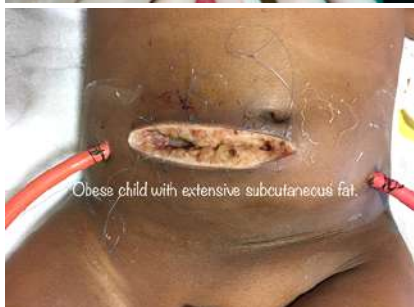
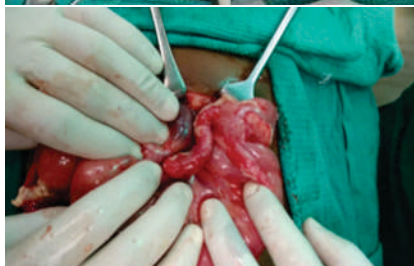
VERTICAL MATTRESS WITH A CANTH LOOP-WITH KNOTS.

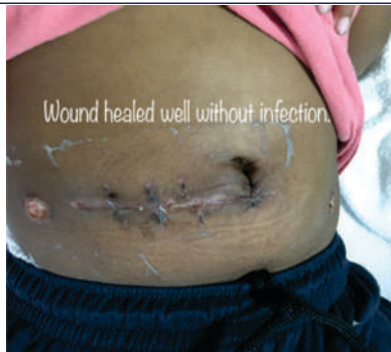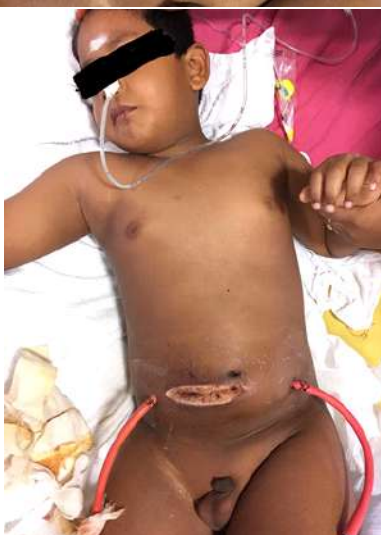TO BE TIED AFTER FIVE DAYS.



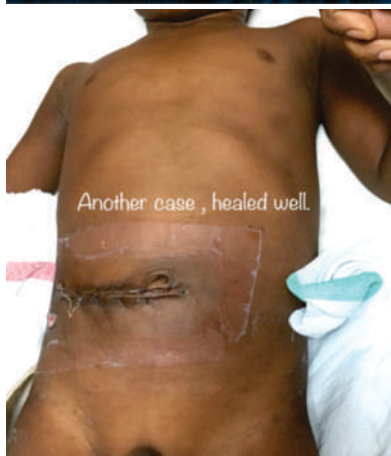Pus in the peritoneal cavity.



Obese child with extensive subcutaneous fat.



Wound healed well without infection.



Another case , healed well.

REFERENCES

1. Healing Initial of Appendectomy Infection Wounds With Aggressive Washing Method.Iraj Feizi , Iraj Poorfarzan,Bita Shabbazzadegan , Firouz Amani et al Iranian Red Crescent Medical Journal. 2013 September; 15(9): 786-8.
2. Wound Infection Incidence in Patients with Simple and Gangrenous or Perforated Appendicitis. Mostafa Mehrabi Bahar,Ali Jangjoo MD,Ahmad Amouzeschi MD,Kamran KavianiFar MD et al. Arch Iran Med 2010; 13 (1): 13 – 16.
3. Chiang RA, Chen SL, Tsai YC, Bair MJ. Comparison of primary wound closure versus open wound management in perforated appendicitis. J Formos Med Assoc. 2006; 105: 791 – 795.
4. Harahsheh B 1 , Hiyasat B, Abulail A, Al-Basheer M. Management of wound infection after appendectomy: are parenteral antibiotics useful? East Mediterr Health J. 2002 Jul-Sep;8(4-5):638-44.
5. van der Werken C 1 , Stassen LP, van Vroonhoven JM. Post-appendectomy wound infection, a solved problem?Neth J Surg. 1989 Oct;41(5):100-3.
6. Shubing W, Litian Z. Preventing infection of the incision after appendectomy by using metronidazole preoperatively to infiltrate tissues at the incision. Am J Surg. 1997 October;174:422-4.