



## PAEDIATRIC BLUNT ABDOMINOPERINEAL INJURIES SUCCESSFULLY MANAGED - CASE SERIES

**Dr. M. Ananthan**

Assistant Professor, Department of Paediatric surgery, Institute of Child Health & Hospital for Children, Madras Medical College, Chennai, India.

### ABSTRACT

Trauma is an important cause of mortality and morbidity in children. Abdominal trauma is the 3rd leading cause of trauma death. Abdominal injuries can have a varied presentation. The first case was a 2 years old male child with gastric perforation and fracture shaft of tibia due to fall of a gas cylinder on him. Laparotomy showed a huge rent in the stomach which was closed after thorough lavage. POP cast was applied for the fracture tibia. Child recovered well and is on follow up. The second case was a 2 year old female admitted with the history of fall of a Television on the abdomen. Investigations revealed features of bowel injury. Laparotomy revealed a rent in the second part of the duodenum, which was closed primarily. The child recovered well and is on follow up. Third case was a 3 year old female child with split perineum and open book fracture of the pelvis due run over by a bus. The patient was treated with reconstruction of the entire perineum along with colostomy, suprapubic cystostomy and external fixation of the pelvis. This child is able to walk normally and continent of urine and feces. Fourth case was a 5 year old boy was admitted with severe injuries to the perineum and lower abdomen along with amputation of the right lower limb below the mid-thigh level with shock. After stabilisation, he was treated with Laparotomy and colostomy. The perineal reconstruction done Pelvic bones were stabilised with external fixators and right mid-thigh amputation was done by the Orthopaedic team. The colostomy closure was done. Now the wounds have healed well and the child is continent. These cases are a small sample of the varied presentation that abdominal trauma can have and with aggressive management morbidity and mortality rates can be reduced.

**KEYWORDS :** Trauma, Aggressive management, Good outcome.

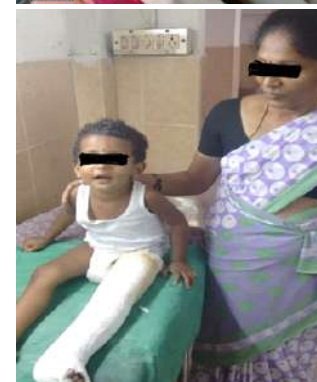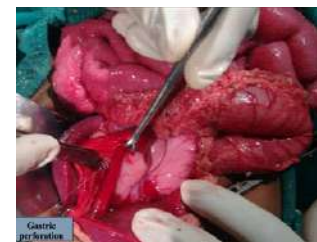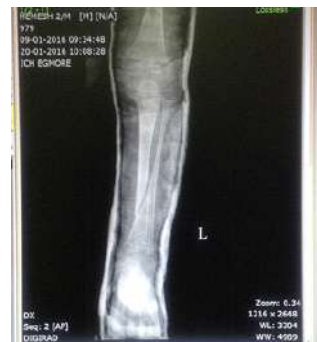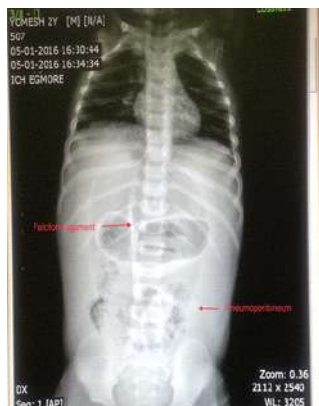### INTRODUCTION

Trauma is one of the leading causes of morbidity and mortality in the paediatric population (1). The abdomen is the third most commonly injured anatomic region in children following head and the extremities (1). Abdominal trauma is associated with significant morbidity and may have a mortality as high as 8.5% (1). The abdomen is the most common site of initially unrecognized fatal injury in a child with trauma (1).

8% to 12% of blunt injured children will have abdominal injury. Fortunately, more than 90% of those with blunt abdominal injuries survive and only 22% of the deaths are related to the abdominal injury. Whereas abdominal injuries are 30% more common than thoracic injuries, they are 40% less likely to be associated with a fatal outcome. The treatment of children with major abdominal injuries has changed significantly in the past two decades.

### GASTRIC PERFORATION

A 2 year old male child was brought with the history of a gas cylinder fallen on his abdomen and left lower limb. The child had just eaten his meals. The child was in hypovolemic shock and was resuscitated with crystalloids, blood transfusion and ionotropes. There were gross abdominal distension with free fluid and deformity in the left lower limb. Investigations revealed pneumoperitoneum and oblique fracture of the lower one third of tibia. Emergency laparotomy revealed food particles all over the peritoneal cavity. A large gastric rent of size 8 x 2 cm was noted on the anterior wall of the stomach towards the greater curvature and a devitalised area of 1 cm near the lesser curvature. After thorough peritoneal lavage, primary closure of the gastric rent and excision and primary closure of the devitalised area done. A POP slab was applied to the left leg. The child recovered well and was discharged.



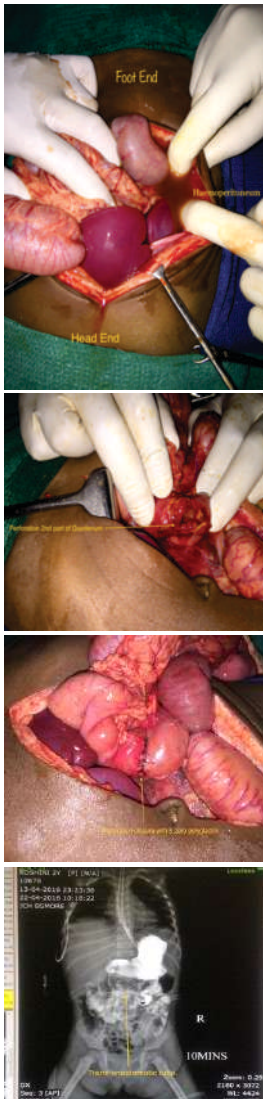
### DUODENAL PERFORATION

2 year old female child was admitted with the history of Fall of a TV on the abdomen. She had 10 episodes of non-bilious vomiting & continuous diffuse abdominal pain. Diffuse tenderness and guarding were noted in the abdomen and the skin didn't have any injury marks. CECT Abdomen- Haemoperitoneum and Bowel injury.

Emergency laparotomy through midline incision was done. There was

a perforation of about 1.5 cm was noted at the second part of duodenum. After freshening up the edges, Perforation was closed with 5 zero polyglactin in single layer extra mucosal suturing. Two nasogastric tubes were inserted through each nostril. One was placed Trans anastomotically into the upper jejunum and another was kept in the stomach. Wide bore drainage tubes were placed in the Morrison's pouch and in the pelvis.

Post operatively, aspiration of the NG tubes done hourly and treated with Antibiotics, Octreotide and Partial parenteral nutrition. She made uneventful recovery.



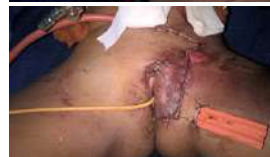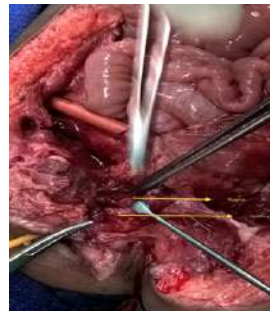
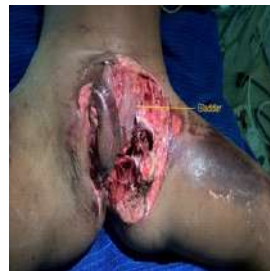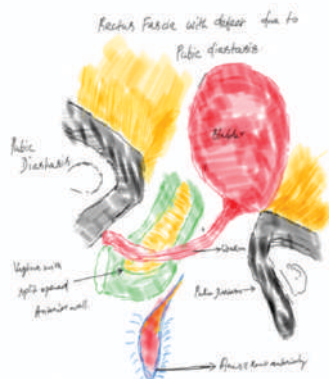
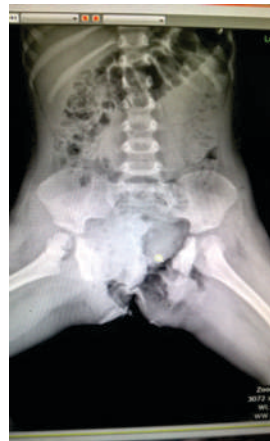**ABDOMINOPERINEAL INJURY.**

3 year old girl was admitted with the history of hit by a van. The child's General condition was poor. The upper abdomen was soft and not distended. A fasciocutaneous defect was noted in the lower abdomen, through which the distended bladder was seen. Pelvic bone open book fracture was seen along with disruption of anterior wall of the ano rectum, perineal body and vagina. Vaginal and urethral orifices were avulsed. Urethra was traced out and found to be intact as a tubular structure amidst the wound. Investigations revealed Fractures in Left superior and inferior pubic rami. Right pubic bone and Femoral neck. After stabilisation of the patient with intravenous fluid and blood, emergency surgery was done. Laparotomy through midline incision to rule out other organ injuries. Bladder catheterised through the traced out urethra along with suprapubic cystostomy. After the Initial pelvic stabilisation with 1 prolene stitches taken through the pubic symphysis, Perineal reconstruction was done organ by organ and layer by layer. Pelvic stabilisation was done with external fixator by the orthopaedic team. Sigmoid loop Colostomy was done. Abdomen closed in layers with difficulty in the lower part because of the fascial defect.

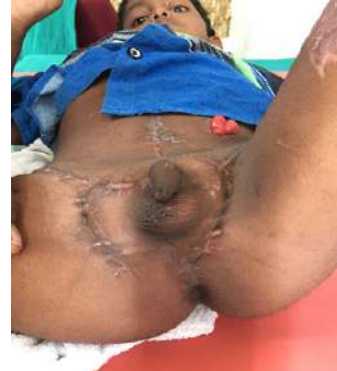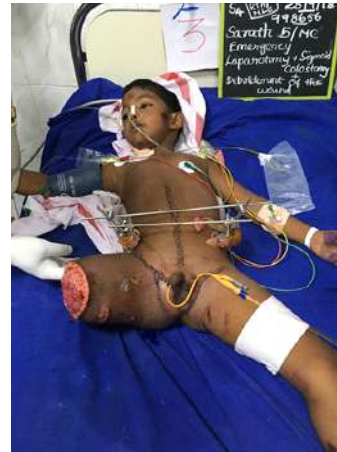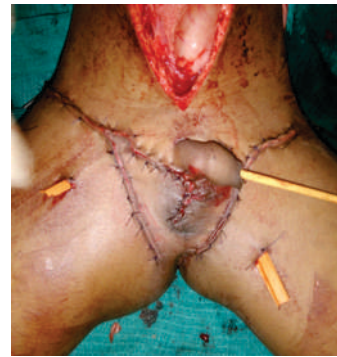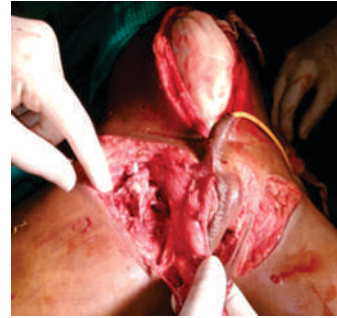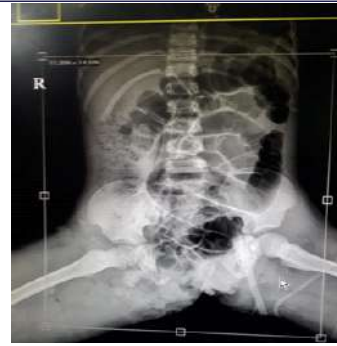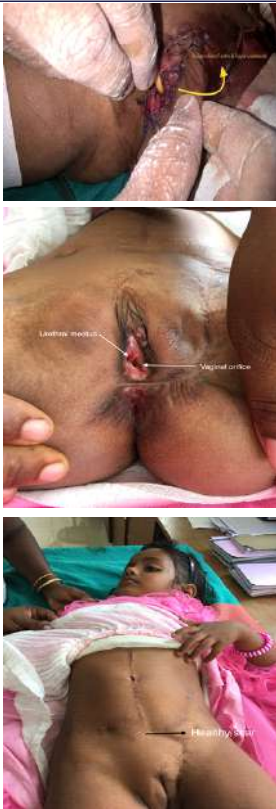Per cutaneous fixation or Fracture neck of the Right Femur was done after 10 days.

After ascertaining the normalcy of the pelvic floor, urethra and distal colonic loop, by CECT Abdomen, Ascending urethrogram, Distal loopogram, Colonoscopy and Cystoscopy, Suprapubic cystostomy tube removal and colostomy closure were done one by one.

Present status of the child. She is now able to walk normally with normal bowel and urinary continence.

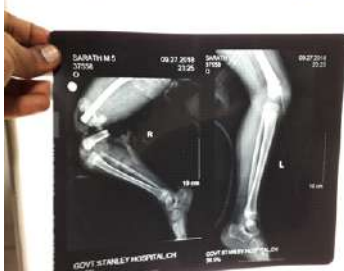
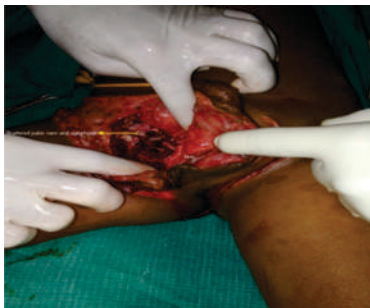


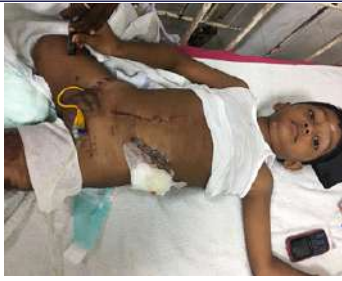

**ABDOMINO PERINEAL INJURY**

This 5 year old boy was admitted with the history of Road traffic accident and sustained severe injuries to the perineum and lower abdomen along with amputation of the right lower limb below the mid thigh level. At the time of admission the was in shock which was aggressively managed with intravenous fluids , blood products , antibiotics and pressor agents. After stabilisation of the cardiovascular status patient was taken up for surgery. The following procedures were done. Laparotomy to rule out associated injuries and for colostomy. As there was total disruption of the perineum, to protect the wound from infectious complications, the colostomy was done. The perineum was reconstructed in a layer by layer manner after wound debridement. Pelvic bones were stabilised with external fixators and right mid thigh amputation was done by the Orthopaedic team. After the healing of perineal wound and the pelvic bones, the external fixators were removed. The colostomy closure was done after evaluating the patency of the rectum. Now the wounds have healed well and the child is continent.





## DISCUSSION

Abdominal trauma accounts for 8- 10% of admissions at paediatric trauma centers. It is the 3rd most common cause of death in paediatric trauma. It is also a common cause for hidden fatal injuries (1).

85% of paediatric abdominal trauma is accounted for by blunt abdominal trauma with motor vehicle accidents being the most common cause followed by sports injuries and fall (2).

Penetrating trauma constitutes the remaining 15% of cases. Gun shot and stab injuries are the most common causes. It has a higher mortality when compared to blunt abdominal trauma.

There are certain anatomical factors which makes abdominal trauma in children relatively more common. Solid organ are larger and more anteriorly placed. They also tend to have a less subcutaneous fat and thinner abdominal wall musculature. They have more pliable rib cage and pelvic bones. The result of these factors is an increase in incidence of solid organ injuries and associated bowel injuries.

History and proper examination may give a clue as to the severity of the injury sustained, for example presence of a patterned abrasion in the epigastrium, the so called lordon sign should raise the suspicion of an injury to the pancreas or duodenum. However it is to be remembered that absence of external signs does not rule out the presence of an intra-abdominal injury. In fact 7.1% of children with normal physical examination had intra-abdominal injuries on CT (2).

Important contributions have been made in the diagnosis and treatment of children with abdominal injury by radiologists with cross-sectional imaging, interventional procedures, and endoscopists. The resolution and speed of computed tomography (CT), screening. Capabilities of focused abdominal sonography for trauma (FAST), and the less invasive percutaneous, angiographic, and endoscopic interventions of non-surgeon members of the pediatric trauma teams have all enhanced patient care and improved outcomes.

Plain X ray abdomen can be done which can show free air, indicating the presence of bowel injury. However presence of free air in an X ray most commonly indicates the presence of a gastric, duodenal bulb or colonic injuries, as only 25 – 33% of children with jejuno ileal injuries demonstrate free air in a plain x ray abdomen.

FAST or focussed abdominal sonography in trauma is a very important adjunct in the identification of solid organ injuries. However, its inability to identify the extent of injury and failure to visualise the retroperitoneum as well its operator dependency limits its efficacy. Holmes et al has documented in his prospective study of 244 patients that FAST has a sensitivity of 82 % and a specificity of 95% , Soudack et al. , in their retrospective study of 313 children have demonstrated a sensitivity of 92.5 % and a specificity of 97% (2). I

CECT abdomen is the investigation of choice in a haemodynamically stable patient , to assess the extent of injury .however, the radiation exposure and its inability to detect accurately bowel injuries is a limiting factor (2).

Management of a child with blunt abdominal trauma is expectant unless there is evidence of ongoing intra-abdominal bleed like tachycardia, hypotension, reduction in urine output and fall in haematocrit or if bowel injury is suspected. Serial abdominal assessment of children should be advocated as bowel injuries may be detected many hours after the inciting event. The duodenal perforation are all treated operatively in a variety of ways depending on the severity of the injury and surgeon's preference. The easiest and safest combination is the "three tube technique": duodenal closure (primary

or anastomosis) with duodenal drainage tube for decompression (tube 1), pyloric exclusion with an absorbable suture via gastrostomy, gastric tube placement (tube 2), and feeding jejunostomy (tube 3) along with several drains placed where leakage might be anticipated. When the duodenum is excluded complete healing of the injury routinely occurs prior to the spontaneous reopening of the pyloric channel. These decrease the incidence of duodenal fistula, reduce the time to GI tract alimentation, and shorten hospital stay. However, rarely Whipple procedure is required for the most severe injuries to the duodenum and pancreas when the common blood supply is destroyed and any possibility of reconstruction is impossible; excluding penetrating trauma, this will rarely occur.

## CONCLUSION

Abdominal trauma in children is a spectrum. From the not too obvious to what was reported above. While it may not be possible to diagnose every injury in a patient with trauma, effort should be taken to not miss the obvious. Aggressive management of the trauma victims leads to better outcome.

## REFERENCES

- (1) Advances in Abdominal Trauma; J.L. Isenhour, MD, J Marx, MD; Emerg Med Clin N Am 25 (2007) 713–733
- (2) Pediatric Major Trauma: An Approach to Evaluation and Management; J.T. Avarello, MD, FAAP, R.M. Cantor, MD, FAAP, FACEP; Emerg Med Clin N Am 25 (2007) 803–836
- (3) Rosen's Emergency Medicine
- (4) Emergency Medicine Manual, 6th Ed; O John Ma & Davis M Kline
- (5) Oxford Handbook of Trauma for Southern Africa; A Nicol & E Steyn