



A RARE CASE OF VALPROATE INDUCED HEPATO-TOXICITY

Dr. V. C. Singel	Professor, Head of Department & Head Of Unit, Department of Medicine, B. J. Medical College, Ahmedabad.
Dr. Kartikeya Parmar	Assistant Professor, Department of Medicine, B. J. Medical College, Ahmedabad.
Dr. Vijay Dhalavaniya	Third Year Resident, Department of Medicine, B. J. Medical College, Ahmedabad.
Dr. Khanjan Patel*	Third Year Resident, Department of Medicine, B. J. Medical College, Ahmedabad. *Corresponding Author
Dr. Swansu Batra	Third Year Resident, Department of Medicine, B. J. Medical College, Ahmedabad.

ABSTRACT

Drug Induced Liver Injury(DILI) can occur owing to a dose dependent or idiosyncratic reaction to a drug. Valproate induced hepato-toxicity can lead to Acute hepatic failure, occasionally can progress to fulminant hepatic failure and may require liver transplantation. Valproate being a commonly used drug, most physicians need to exert a cautious approach for judicious use of the drug. Hereby, we aim to discuss different manifestations of Valproate induced Hepato-toxicity and it's medical management.

KEYWORDS : Valproate hepato-toxicity, hyperammonemia, L-carnitine, Reye like syndrome, Hy's law.

INTRODUCTION:

Valproic Acid (valproate) is a branched chain organic acid, used for treatment of epilepsy, migraine headache prophylaxis, bipolar disorders and is a renowned cause of several distinctive forms of acute and chronic liver injury. Valproate acts by increasing levels of gamma amino butyric acid(GABA), a major inhibitory neuro-transmitter in human brain. Valproate has multiple side effects and clinically significant drug interactions; common side effects include headache, insomnia, nervousness, somnolence, tremor, blurred vision, nausea, weight gain and rash. More serious side-effect includes fatal liver damage .

Valproate induced hepato-toxicity can occur in following three :

Valproate can cause hepatotoxicity by 3 mechanisms

1: HYPERAMMONEMIA WITH MINIMAL OR NO EVIDENCE OF HEPATIC INJURY.

This syndrome presents with progressive and episodic confusion followed by obtundation and coma. Diagnosis can be made by elevation in serum ammonia with normal serum amino-transferases and bilirubin levels. This syndrome resolves within few days with stopping of drug and more rapidly with carnitidine supplementation.

2:ACUTE HEPATOCELLULAR INJURY WITH JAUNDICE AND MIXED PATTERN ENZYME ELEVATION.

Onset is usually within 1-6 months of starting valproate. Mixed pattern or hepato-cellular pattern of enzyme elevation may be seen . Fever, rash, eosinophilia are rare. Liver histology s/o microvesicular steatosis with central lobular necrosis, mild to moderate inflammation and steatosis. Intravenous carnitine can be useful if given soon after presentation.

3:ACUTE HEPATIC INJURY WITH REYE LIKE SYNDROME

Usually occurs in children on aspirin like agent following influenza or varicella infection. Child on valproate develops fever, lethargy followed by confusion, stupor and coma.

Laboratory finding s/o raised in ammonia level with marked ALT elevation with normal bilirubin level.

Incidence of valproate induced hepatotoxicity in United States in 2016 was 3060 single exposures. The international frequency of valproate toxicity is unknown. Retrospective studies indicate that patients under 2 years of age, those receiving multiple anticonvulsants, and children with underlying developmental disorders and inborn errors of metabolism may be at increased risk

Clinical Features Of Valproate Induced Hepato-Toxicity:

Symptoms are accounted to hepatocyte damage, biliary stasis, hyperammonemia.

Usually occur within 1-6 months of starting drug.

Clinical presentation usually begins in form of lethargy, nausea, vomiting. Soon, jaundice, fever, rash, itching, abdominal pain may occur.

Symptoms depend on form of hepato-toxicity which has varied manifestations in different patients.

Patients with hyperammonemia as predominant form of injury present with altered sensorium, coma, features of hepatic encephalopathy. While those with hepatocellular or mixed pattern present with symptoms of obstructive jaundice like pruritus, right hypochondrial pain, pale stools, dark urine and sclera.

Children with features of hepatic injury like reye syndrome present with fever, lethargy, confusion, coma.

II. CASE REPORT:

A 22 year old male, presented to the emergency room of Civil Hospital Ahmedabad on 6/1/2019 with chief complaints of: yellowish urine and sclera, anorexia, generalized weakness and easy fatiguability and rash since 10 days Patient had no history of nausea, vomiting, fever, abdominal pain, loose stools.

Patient was a known case of seizure disorder since 2010 and

was on tab. Phenytoin (300mg) since two years, which he stopped in 2012. He had 3-4 episodes of seizures for which he was started on tablet valproate (500mg) in October 2018.

Within 2 months of initiation of tab. Valproate patient started developing generalized weakness, yellow discoloration of urine and sclera, skin rash. He was admitted for the same at some local hospital in December 2018 and was later on referred to civil Hospital Ahmedabad for further evaluation and management in January 2019.

EXAMINATION

On examination patient was conscious, oriented.

Temperature-Normal

Pulse-82/min

Blood pressure-112/70 mmHg

Tongue- pale

Nail-pale

Bulbar Conjunctiva, sclera- icterus present

Respiratory system-Bilateral air entry present

Cardiovascular system-First and second heart sounds present

Abdominal examination-No palpable hepato-splenomegaly

No obvious enlargement or swelling Central nervous system-

Conscious, oriented. Tone, reflexes, power, sensations - WNL

LABORATORY INVESTIGATIONS

Hb (gm/dl)	Total wbc count (/cumm)	Bilirubin(mg/dl)			SGOT (U/L)	SGPT (U/L)	ALP (U/L)	Albumin (gm/dl)	INR	Creatinine (mg/dl)	Platelet (lacs)	Sodium (meq/L)
		Direct	indirect	Total								
10.3	18,100	12	3	15	1745	2150					2.2.72	
5	25,500	14	2.1	16.1	704	1550		5.3			3.8	
7	4100	18	8	26	232	876	125	2.26	1.6	0.8	2.6	139
10	4600	28	8	36	163	312	766	3.1	2.32	1.2	2.8	141
8.5	5200	18	4	22	164	165	1141	2.8	1	1.24	2.6	128

Tests for HBSAG, HCV, HIV, HAV, HEV were negative.

Tests for autoantibodies ASMA, IgG, ANA, AMA were negative.

Serum ceruloplasmin was normal

Serum ammonia – 58 μmol/L

IMAGING STUDIES AND OTHER INVESTIGATIONS

ECG, Chest XRAY-Normal

USG Abdomen and pelvis-NAD, with no signs of biliary obstruction

CECT Abdomen and pelvis, MRCP-NAD

Slit lamp examination -No evidence of Kayser Fleischer ring. 2D Echo-NAD

Liver Biopsy-Lobular architecture of hepatic tissue with extensive sinusoidal dilation, intrahepatic cholestasis and mild hepatic steatosis. No granulomatous lesion or sclerotic changes seen.

COURSE IN HOSPITAL

Patient was admitted at civil hospital Ahmedabad on 6/1/2019. Routine investigations were suggestive of obstructive jaundice. Tab. Valproate was stopped and tab. Levetiracetam was started in its place. Initially supportive treatment was given in form of tab ursetor(ursodeoxycholic acid) 300mg thrice a day, Liquid lactulose 30cc thrice a day, lactulose enema, intravenous fluids containing dextrose over a period of 5 days. Intravenous N-Acetylcysteine over 21 hours was given in form of divided doses ie 50mg/kg over 1 hr, 150 mg/kg over 4 hrs, 100mg/kg over 16 hrs. During this period, complete workup was done. All other causes of jaundice ie infectious, metabolic, genetic ;mainly of obstructive variety were ruled out. A final diagnosis of valproate induced hepato-toxicity was established post liver biopsy.

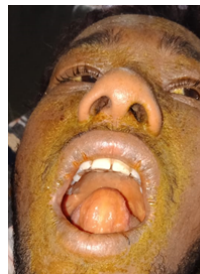


Image 1: Icteric Sclera And Under-surface Of Tongue

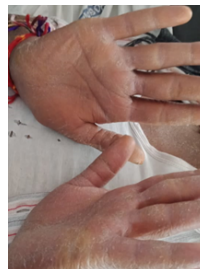

Image 2: Rashes In Palms And Soles Secondary To Vaproate Exposure

Patient was started on carnitine and other anti- oxidants. Carnitine was given intravenously in the loading dose of 100mg/kg over 30 minutes and 15mg/kg every 4 hours till 3 days.

As patient's liver function test was not improving significantly and had developed DILIN grade 4 (Severe) Acute Hepatic failure, patient was referred to IKDRC at civil hospital ahmedabad for liver transplantation.

I. DISCUSSION REGARDING TREATMENT OF VALPROATE INDUCED HEPATO-TOXICITY

The offending drug i.e. valproate is to be stopped firstly.

Importantly, carnitine appears to be a specific antidote for valproate hepatotoxicity.

L-Carnitine, a water soluble amino acid, is indicated in the management of patients that develop hyperammonemia (serum ammonia concentrations >80 μg/dL) and hepatic toxicity associated with both therapeutic dosing and acute overdose of valproic acid. Valproic acid is commonly used in the management of seizure and psychiatric mood disorders. Deficiencies in dietary intake and endogenous production of L-carnitine increase the risk of developing hyperammonemia following valproic acid exposure. High ammonia concentrations may produce encephalopathy characterized by altered mental status or seizures and possibly death if not recognized. Prompt administration of carnitine (particularly when given intravenously) improves survival in acute valproate hepatotoxicity. The typically recommended dose is 100 mg/kg intravenously over 30 minutes (but less than 6 grams), followed by 15 mg/kg every four hours until clinical improvement. Other supportive management for liver failure includes intravenous dextrose containing fluids, Syrup lactulose, ursodeoxycholic acid. N-acetylcysteine an anti-oxidant commonly used in paracetamol poisoning , can be used in acute hepatic failure due to it's hepato-protective

effect. Patients not improving with medical management and progressing towards acute hepatic failure may require liver transplantation at the earliest.

IV. KEY MESSAGE

Valproate induced hepato-toxicity is a diagnosis of exclusion. Only after ruling out all other causes, should a patient be diagnosed as a case of valproate toxicity. Dosage of valproate should be appropriate to age, condition and other factors. Liver function tests mainly amino-transferase levels should be frequently monitored in all patients. Valproate should be avoided in patients with known liver diseases, alcoholism, enzyme defect disorders. According to Hy's law, patients with drug induced hepato-toxicity, have 10% or more chance of progressing towards hepatic failure may require liver transplant. Thus, early diagnosis may aid in improving prognosis.

REFERENCES:

- 1 Bethesda (MD): National Institute of Diabetes and Digestive and Kidney Diseases; 2012 .LiverTox: Clinical and Research Information on Drug-Induced Liver Injury <https://www.ncbi.nlm.nih.gov/books/NBK548284/>
- 2 Zimmerman HJ, Ishak KG. Valproate-induced hepatic injury: analysis of 23 fatal cases. *Hepatology* 1982; 2: 592-597
- 3 Sherlock's Diseases Of The Liver And Biliary System Chapter 24: Drug Induced Liver Injury
- 4 University Of Maryland School Of Pharmacy; July 2012