



A RARE CASE OF RHINITIS CASEOSA AND FUNGAL SINUSITIS

Dr. M. K. Rajasekar	Professor Dept Of Ent, Sree Balaji Medical College, Chennai
Dr. Sridhara Narayanan*	Professor Dept Of Ent, Sree Balaji Medical College, Chennai *Corresponding Author
Dr. Shaheera	Junior Resident Dept Of Ent, Sree Balaji Medical College, Chennai

ABSTRACT

Rhinitis caseosa also called as nasal cholesteatoma is a misnomer. The essential criteria for diagnosing rhinitis caseosa are -1) nasal polyp and offensive purulent discharge and cheesy material ; 2) clinical or radiological evidence of bony expansion of the sinus walls and 3) demonstration of heterogenous opacification of the paranasal sinuses with areas of hyper-attenuation.

Fungal sinusitis is a distinct clinical entity characterized by inflammation of the sinus mucosa caused by fungal infection like aspergillus, mucormycosis, candida, scedosporium, penicillium.

We hereby present a case of 68 years old male presented to OPD with left sided nasal obstruction, nasal discharge and anosmia, for 4 months. Patient was evaluated and underwent Microdebrider assisted polypectomy with FESS. Early recognition and prompt initiation of combined medical treatment and surgical intervention done to prevent its aggressive nature and propensity for orbital and intracranial extension.

KEYWORDS : Rhinitis Caseosa, nasal Cholesteatoma, fungal Sinusitis

INTRODUCTION:

Rhinitis caseosa is a chronic inflammatory condition of the nose due to obstruction of nasal passage, all major sinuses due to stenosis or adhesions or synechiae leading to stagnation of secretions and constant exfoliation of nasal mucosa collected together to undergo chemical changes and putrefaction resulting in the formation of caseous material in nasal cavity. It is associated with Sinusitis, foreign body , fungal infection , Tb, Syphilis, polyp degeneration.

Fungal sinusitis is a distinct clinical entity characterized by inflammation of the sinus mucosa caused by fungal infection like aspergillus (fumigatus, niger, flavus), mucormycosis, candida (albicans), scedosporium, penicillium. There are different types of fungal sinusitis: fungal mycetoma, allergic fungal, chronic indolent and fulminant sinusitis. Allergic fungal rhinosinusitis is the most common entity. Aspergillois is the most common fungal infection. Of these aspergillus fumigatus is the most common fungal pathogen. Maxillary sinuses are commonly involved.

CASE REPORT:

A 68 years old male presented to OPD with left sided nasal obstruction, nasal discharge and anosmia, for 4 months.

On examination:

- Anterior rhinoscopy – DNS-Right, foul smelling cheesy material filling left nasal cavity associated with blood stained discharge.
- Lt maxillary region –tenderness +

DIAGNOSTIC NASAL ENDOSCOPY:

RIGHT -DNS with spur, Accessory ostium
LEFT- foul smelling cheesy material filling left nasal cavity associated with blood stained discharge, polypoidal Middle Turbinate and pale greyish glistening mass seen in middle meatus

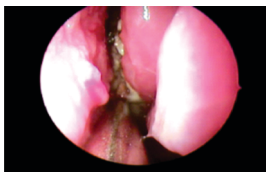

FIG1: Foul smelling cheesy material seen filling left nasal cavity

CT PNS:

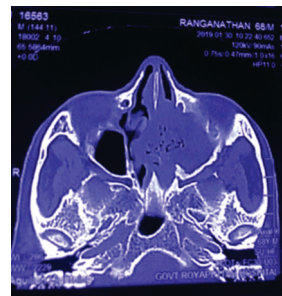


FIG2: Erosion of bony part of posterior nasal septum noted with atrophy of inferior turbinate

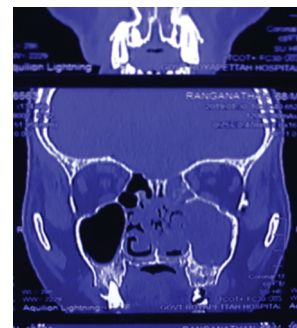


FIG3: Soft tissue density lesion noted completely filling left maxillary , frontal and ethmoidal sinuses extending through left maxillary ostium into left nasal cavity with few air pockets.Sclerotic of left maxillary sinus

- No evidence of intracranial / intraorbital extension.

SURGICAL MANAGEMENT:

- The aim of surgery was to remove oedematous mucosa and caseous debris, establish sinus aeration
- Patient underwent Microdebrider assisted polypectomy with FESS under GA. The maxillary sinus L was found to be filled with cheesy material which was removed after middle meatal antrostomy. The walls of the maxillary sinus was found to be intact. and specimen sent for Histopathological examination, KOH mount.

Disease was evident as hypertrophic mucosa or polyp in the sinonasal cavities surrounding necrotic avascular, caseous, greenish-green casts. The ethmoids and septum were involved in the caseous process. These caseous casts were removed

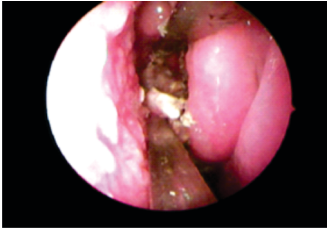


FIG.4.Cheesy material taken for HPKOH

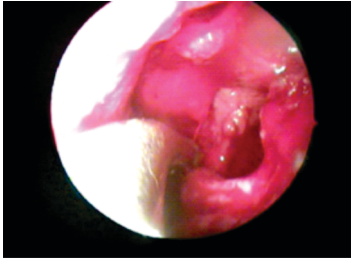


FIG.5.Left Middle Meatal Antrostomy done

- koh mount: fungal elements seen.
- HP REPORT: Multiple sections show oedematous respiratory epithelium. The underlying edematous tissue shows lobules of mucous glands and granulation tissue with foci showing fragments of fungal colonies enclosing dichotomously acute angle branching septate fungal filaments. Histologically squamous elements could not be identified in them – suggestive of Aspergillus Fungal lesion and Nasal cholesteatoma.
- CT scan and Nasal endoscopes increased the awareness to this disease spectrum. The diagnosis was based on an otolaryngological, imagistic but histopathological examination suggestive of fungal lesion make the certain diagnostic in this case.

DISCUSSION:

Duplay coined the term Rhinitis caseosa. A most exhaustive review is to be found by Eggston and Wolff (1947). They concluded rhinitis caseosa to be a secondary condition which could be consequent to any primary pathology causing an obstruction to the discharge of secretions from the para-nasal sinuses. Their studies revealed that In patients with extensive bilateral ethmoidal polyposis this condition is more common. Accumulation of secretions in the nasal cavity is due to the presence of polyp which causes obstruction to the normal drainage mechanism of paranasal sinuses. yellow-brown, cheesy, "Caseous" material were found within the nasal cavities of these patients behind the nasal polypi. Subsequent reports have since emphasized the bony expansion and erosion of the sinus walls (Seeb, 1977), and also the extensions into the orbit and the cranial cavity (Ladagao, 1979; Wolfowitz, 1973). DNE done to see the presence of cheesy foul smelling material in the nasal cavity. CT PNS is indicated if there is suspected bony erosion in xray pns. If not treated it can lead to orbital and intracranial complications. Removal of cheesy material and obstructed lesion is corrected surgically with alkaline douching for 3 weeks and oral penicillin antibiotic for one week.

Fungal sinusitis is classified into invasive and non invasive. Invasive fungal sinusitis is classified into acute Invasive fulminant fungal sinusitis and chronic or indolent invasive fungal sinusitis and are characterized by black necrotic turbinate, dark, thick, greasy material found in the sinuses.

Invasive infections can cause tissue invasion and destruction of adjacent structures (eg, orbit, CNS). Patient is immunocompromised in invasive fungal sinusitis.

Noninvasive fungal sinusitis is classified into sinus mycetoma, AFRS and saprophytic colonization. Most common fungus seen in non invasive (fungal ball) is *Aspergillus fumigatus*, its otherwise known as Aspergilloma. Most common sinus involved is Maxillary sinus. Patient is immunocompetent and there is no reaction to fungus. CT PNS done reveals heterogenous opacification associated with bony thickening or sclerosis of sinus walls involved and its confirmed by HPS. Surgical removal of fungal ball is required and antifungal therapy is not required

CONCLUSION:

Our purpose was to emphasize the need of early recognition and prompt initiation of combined medical treatment and surgical intervention with the intent to preserve the involved vital structures and to prevent its aggressive nature and propensity for orbital and intracranial extension

- Surgery aims at clearing the sinus and establishing aeration. The prognosis is excellent provided aeration and drainage of sinuses can be maintained
- Adjuvant steroids - local and systemic - have been advocated for fungal sinusitis in order to reduce recurrences.