



## NON-SURGICAL ENDODONTIC TREATMENT OF EXTRAORAL ORO-CUTANEOUS SINUS TRACT: A CASE REPORT

**Dr. Herojit Naorem**

Post graduate, Department of Pediatric and Preventive Dentistry, Inderprastha Dental College and Hospital, Ghaziabad.

**Dr. Kapil Gandhi\***

Professor and Head, Department of Pediatric and Preventive Dentistry, Inderprastha Dental College and Hospital, Ghaziabad \*Corresponding Author

**Dr Ritika Malhotra**

Reader, Department of Pediatric and Preventive Dentistry, Inderprastha Dental College and Hospital, Ghaziabad

**Dr. Rishabh Kapoor**

Senior Lecturer, Department of Pediatric and Preventive Dentistry, Inderprastha Dental College and Hospital, Ghaziabad

**Dr. Babita Jangra**

Senior Lecturer, Department of Pediatric and Preventive Dentistry, Inderprastha Dental College and Hospital, Ghaziabad

### ABSTRACT

The development and progression of endodontically induced periapical lesions is clearly associated with the presence of microorganisms in the root canal system. The present case report discusses diagnosis and treatment of an extraoral cutaneous sinus tract of odontogenic origin in relation to a mandibular right permanent first molar with closed apex (diagnosed as non-suppurative periradicular periodontitis with an extraoral cutaneous sinus tract opening in the left side of mandibular posterior region). Conservative endodontic therapy was performed using triple antibiotic paste as intracanal medicament. Patient responded well with the treatment approach and the cutaneous lesions was healed uneventfully. In the absence of any clinical symptom complete obturation was done in mandibular right first permanent molar. Patient was kept on regular follow-up.

**KEYWORDS :** periapical lesion, extraoral sinus tract, odontogenic, non-surgical endodontic treatment.

### INTRODUCTION:

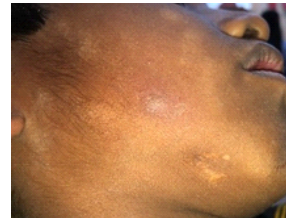Oro-cutaneous fistulas or cutaneous sinus, a tract of dental origin, is an unusual, but the well-documented condition that usually needs dental treatment. The only way of reducing the possibility of further complications such as sepsis and osteomyelitis is well-timed diagnosis and prompt treatment.<sup>1</sup>

In the root canal system the presence of microorganisms is clearly associated with the development and progression of endodontically induced periapical lesions. To manage such cases there are surgical and non-surgical methods. Ideally, a non-surgical method should initially be performed. The rate of success of the non-surgical endodontic management method is totally centered on proper cleaning, shaping, asepsis and filling of the root canals. Several studies described that good healing of periapical diseases can only be achieved by proper sterilization of the root canal and periradicular region.<sup>2</sup> In order to sterilize the infected root dentine, especially the deep layers, antibacterial medicaments are beneficial. In a retrospective study by Bose et al., showed that  $\text{Ca}(\text{OH})_2$  and triple antibiotic paste, can aid further in development of the pulp dentin complex when used as an intracanal medicament in immature necrotic teeth and mature teeth because of their antibacterial properties.<sup>3</sup>

Coronal microleakage and incomplete biomechanical preparation of canals have been identified as another major cause of persistent periradicular disease and failure in endodontic therapy.

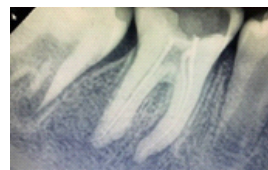### CASE REPORT

A 10-year-old patient reported to the Department of Pediatric and Preventive Dentistry, Inderprastha Dental College and Hospital, Sahibabad, with a chief complaint of extra oral swelling in the right submandibular posterior region of face [Figure 1]. Patient went to the local dentist and was given symptomatic treatment for the same and later root canal therapy was

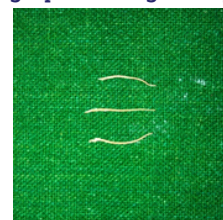


**Figure 1: Extraoral pre-operative photograph - lateral view.**

carried out. After one month swelling along with pain was noticed on the right side of the face and later it subsided after taking medication. Again the same conditions occurred after 3 months. On intraoral examination swelling on the buccal side right permanent mandibular first molar caries on the distal side of first permanent premolar was seen. An intraoral periapical radiograph revealed associated periapical infection with incompletely filled canals in 36 [Figure 2]. Access opening was done on the same day and GP cones were taken out using H-files [Figure 3] followed by working length determination and intracanal medicament were placed.

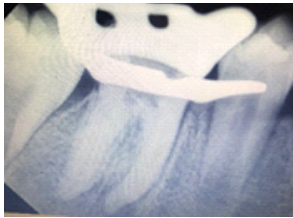

**Figure 2: Radiograph showing incomplete obturation**



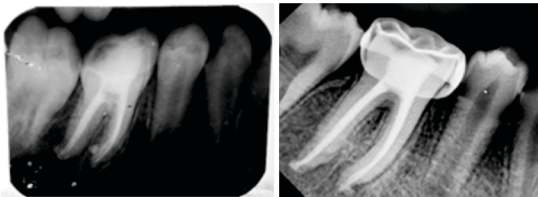
**Figure 3: Retrieved GP cones**

BMP was performed with copious irrigation using 3% sodium hypochlorite (NaOCl) to remove the remaining necrotic pulp tissues. The canal is dried with paper points and triple antibiotic paste [Figure 4] was placed within the canals. Commercially prepared chemotherapeutic agents namely, ciprofloxacin (Cifran 500 mg, Ranbaxy Laboratories Ltd., India), Metronidazole (Metrogyl 400 mg, J.B. Chemicals and Pharmaceuticals Ltd., India) and Minocycline (Minoz 100 mg, Ranbaxy Laboratories Ltd., India) were used.



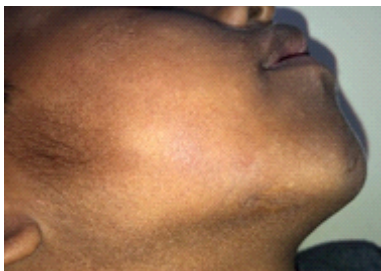**Figure 4: Radiograph showing triple antibiotic paste placed**

After the removal of the enteric coating and the capsule that encloses the drug products, each of the drugs was pulverized using a mortar and pestle. Patient was kept on regular follow-up. In subsequent appointment swelling was found to be reduced. Patient after 4 weeks revealed significant healing. The excess tissues were removed using a scalpel (no.15) and the tooth was non-tender to percussion. At this appointment, the tooth was reopened, the antibiotic paste removed and the canal of permanent molar with was obturated with GP and stainless steel crown was delivered after 3 days [Figure 5].



**Figure 5: Radiograph showing obturation with GP cones and stainless steel crown**

Clinical examinations showed no sensitivity to percussion or palpation and the soft-tissues were healthy and post-operative radiographs showed the progressive process of healing. [Figure 6]



**Figure 6: Post-operative photograph - lateral view**

## DISCUSSION

A periapical dental abscess may be originated by caries, periodontal disease, trauma, or thermal and chemical injuries. An intra-oral or extra-oral sinus can develop, depending on the path of the inflammation, which is dictated by surrounding muscular attachment and fascial planes.<sup>4,5</sup>

The position of dental sinuses is generally anatomically adjacent to the causative tooth. Sometimes, the opening of the sinus tract may be located at a far distance from the dental infection, which makes the diagnosis challenging, particularly with respect to intact teeth. The role of microorganisms in the development and spread of periapical diseases is well-documented in the literature. It is noted that

appropriate sterilization of the root canals and periradicular region result in uneventful healing of periapical diseases. Therefore for the successful outcome of root canal treatment, the microorganisms within the root canal system should be eliminated.<sup>2</sup>

In the present case report, a triple antibiotic paste was used as intracanal medicament. After its application, the symptoms were resolved. Since the overwhelming majority of bacteria in the deep layers of the infected dentine of the root canal wall consist of obligate anaerobes, metronidazole was selected as the first choice among antibacterial drugs. It is reported that metronidazole can penetrate the deep layers of carious lesions and disinfect the lesions *in vivo* and diffuse throughout the dentine<sup>6</sup> as the microbial flora of the root canal with a periradicular lesion is multifaceted in nature, metronidazole alone cannot eradicate all bacteria signifying that other drugs may be required to sterilize the infected root dentine. Thus, ciprofloxacin and minocycline were required to sterilize the infected root dentine in addition to metronidazole. A combination of antibiotics might also drop the likelihood of the development of resistant bacterial strains.<sup>7</sup>

## Summary

Failed root canal treatments are a consequence of microleakage, inadequate cleaning and shaping and poor quality obturations. The usage of an amalgamation of antibiotic drugs in the tooth with persistent sinus tract contributes excellent clinical results.

## REFERENCES

1. Qazi SS, Manzoor MA, Qureshi R, Arjumand B, Hussain SM, Afridi Z. Nonsurgical endodontic management of cutaneously draining odontogenic sinus. *J Ayub Med Coll Abbottabad* 2006;18:88-9.
2. Manuel ST, Parolia A, Kundabala M, Vikram M. Non-surgical endodontic therapy using triple-antibiotic paste. *Kaen Dent J* 2010;33:2
3. Bose R, Nummikoski P, Hargreaves K. A retrospective evaluation of radiographic outcomes in immature teeth with necrotic root canal systems treated with regenerative endodontic procedures. *J Endod* 2009;35:1343-9
4. Mittal N, Gupta P. Management of Extra Oral Sinus Cases: A clinical Dilemma. *J Endod*. 2004;30(7):541-7.
5. Sheehan DJ, Potter BJ, Davis LS. Cutaneous Draining Sinus Tract of Odontogenic Origin: Unusual Presentation of a Challenge Diagnosis. *South Med J*. 2005;98(2):250-2.
6. Sato I, Ando-Kurihara N, Kota K, Iwaku M, Hoshino E. Sterilization of infected root-canal dentine by topical application of a mixture of ciprofloxacin, metronidazole and minocycline *in situ*. *Int Endod J* 1996;29:118-24.