

SMALL BOWEL OBSTRUCTION SECONDARY TO PARAVESICAL HERNIA

Dr Deepak Kumar Jha

senior resident deptt. of gen surgery NBMC west Bengal

ABSTRACT

Bowel obstruction in the setting of the unscarred abdomen can be due to a wide variety of causes. Internal hernias are a rare cause of bowel obstruction with paravesical hernia being exceedingly rare. Paravesical hernia should form part of the differential diagnosis in the patient presenting with bowel obstruction. Prompt management and reduction of the incarcerated bowel are essential. This will prevent further complications especially related to bowel ischemia.

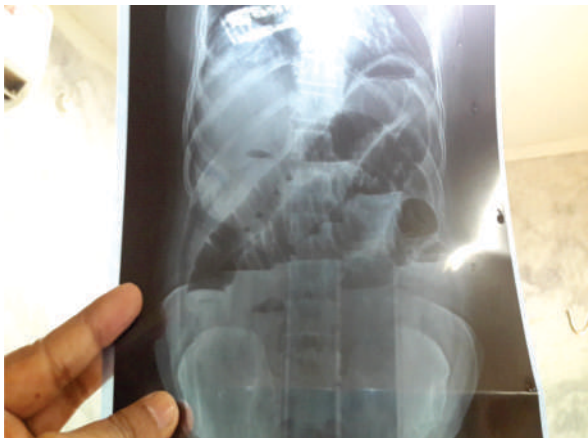KEYWORDS :**1)INTRODUCTION**

Internal herniation is a rare cause of small bowel obstruction. It should form part of the differential diagnosis especially in a previously unscarred abdomen. Paravesical hernia is exceedingly rare. This type of hernia involves herniation of a viscus between the median and medial umbilical ligament. Preoperative diagnosis of these internal hernias is extremely difficult. Computed tomography (CT) scan may suggest the diagnosis but often the findings are not specific and the diagnosis is only made on table.

2)CASE REPORT

A 45 year old male presented with a one week history of abdominal pain. He had associated bilious vomiting, abdominal distension and obstipation.

No significant past medical or surgical history was noted. On examination the patient was dehydrated with a blood pressure 139/89, pulse rate of 99, temperature of 37.2 °C. His abdomen was distended, no masses were palpable. The abdomen was tympanic on percussion. Sluggish bowel sounds were auscultated. There was no evidence of peritonism. Rectal exam revealed an empty rectum. Chest X-ray and Abdominal X-ray revealed no free air. Features suggestive of small bowel obstruction most likely at level of terminal ileum was noted. There were multiple air fluid levels with an absence of air in rectum.(pic 1)



PIC 1.

Blood results were within normal range except for a mildly elevated serum TLC count. The patient was resuscitated and taken to theatre for exploration via a midline laparotomy. A loop of terminal ileum was trapped in paravesical hernia causing small bowel obstruction (Fig. 2). The bowel was necrosed and the containing segment of ilium was resected and anastomosed. The hernial ring was a 2 cm × 2 cm defect in

the prevesical fascia. On digital exploration of defect after reduction of the incarcerated bowel, the sac was found to run laterally to the bladder and no communication to vesicle cavity was noted. The paravesical hernia was repaired with 2/0 Polydioxanone (PDS). Pelvic drain was placed and abdomen closed. The patient made an uneventful post operative recovery.

3)Follow up

At surgical outpatient department two weeks post operatively the patient was well and discharged from surgical care.

4)DISCUSSION

An internal hernia (IH) is a protrusion of intestines or other abdominal organs through a normal or abnormal orifice in the peritoneum or mesentery, occasionally leading to strangulation or incarceration. Internal hernias (IH) are a rare cause of acute abdomen and intestinal obstruction in adults. IH has a reported autopsy incidence of 0.2 to 0.9% and is the cause of small bowel obstruction in 0.6 to 5.8% of the cases^[1]. Internal abdominal herniations can be either acquired through a trauma or surgical procedure or related to congenital peritoneal defects. The classification system of internal abdominal herniations by Ghahremani is now well accepted. Internal abdominal herniations can be separated into six groups: Paraduodenal hernias (50–55% of internal abdominal herniations), hernias through the foramen of Winslow (6–10%), transmesenteric hernias (8–10%), pericecal hernias (10–15%), intersigmoid hernias (4–8%), and paravesical hernias (<4%)^[2].

The supramesical fossa lies between the median umbilical ligament and the medial umbilical ligament. The inferior boundary is formed by a peritoneal fold, part of which is the transverse fold of the bladder.

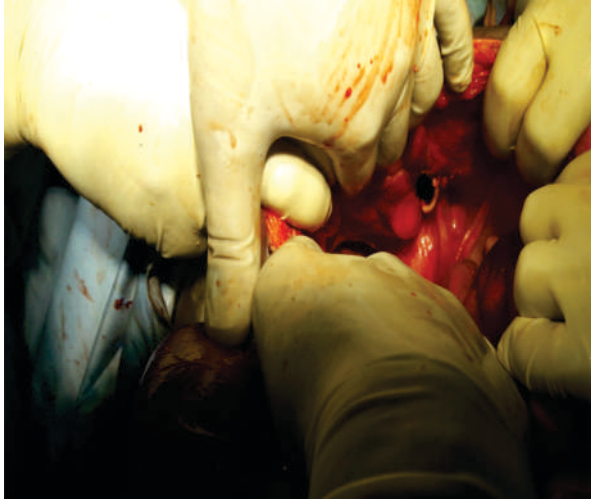
The fossa may go on to form a deep sac. If the hernia occurs in the superior portion of the fossa it may result in an external hernia. The internal hernias extend into the space of Retzius. These hernias can be prevesical, paravesical or even intravesical^[3].

Supramesical hernias are the cause of most pelvic hernias. Approximately 60 cases of supramesical hernias have been reported to date. Paravesical hernias have not specifically been documented.

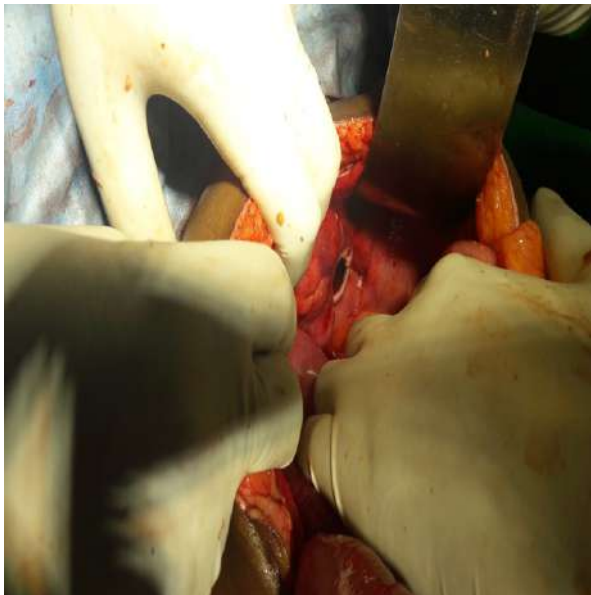
Preoperative diagnosis of these hernias may be challenging and the vast majority of cases are diagnosed at exploration in theatre. Preoperative diagnosis is possible with CT scan or MRI^[4]. CT is currently the best imaging technique for detecting these hernias. The CT scan may show loops of bowel near the bladder^[5]. However if obtaining a CT scan will significantly delay exploration of the patient then it is better to proceed to

exploration as further delay may compromise already marginal bowel. If prompt resuscitation and exploration are not carried out the bowel may become gangrenous and require bowel resection. This will add to overall morbidity of the procedure^[6].

This condition has been reported to be diagnosed and treated laparoscopically^[7]. In our patient however this would have been impossible due to the severe distension of small bowel. The treatment is release of the intestinal obstruction and closing the hernia defect. Attempts to excise the hernia sac are probably unnecessary. Freshening of the edges and simple closure of the defect using continuous or interrupted stitches with non-absorbable sutures is sufficient^[8].



Pic 2



Pic 3

5) CONCLUSION

The case demonstrates a rare cause of small bowel obstruction. The descriptions in the literature of small bowel obstruction secondary to internal supravesical hernia are limited to case reports. Preoperative diagnosis of these internal hernias remains challenging. The main learning point from this case is that in the setting of complete bowel obstruction delay in definitive management should be avoided. Imaging has been of limited utility in cases of acute intestinal obstruction; moreover, interpretation of imaging features is operator dependant. Speed is essential as bowel that incarcerated may become gangrenous.

Ethical approval

Ethics committee approached- No need for ethics approval as this is a case report which involved standard care.

Consent

Written informed consent was obtained from the patient for publication of this case report and accompanying images. A copy of the written consent is available for review by the Editor-in-Chief of this journal on request.

Author contribution

Dr Deepak kumar jha—compiled the manuscript and was involved in the primary management of the case;

REFERENCES

1. Meyers M.A. 4th edition. Springer Verlag; New York, NY: 1994. Dynamic Radiology of the Abdomen: Normal and Pathologic Anatomy. [Google Scholar]
2. Ghahremani G.G. Abdominal and pelvic hernias. In: Gore R.M., Levine M.S., editors. Textbook of Gastrointestinal Radiology. 2nd edition. Saunders; Philadelphia, PA: 1994. [Google Scholar]
3. Skandalakis J.E., Gray S.W., Burns W.B., Sangmalee U., Sorg J.L. Internal and external supravesical hernia. *Am. Surg.* 1976;42(February (2)):142e6. [PubMed] [Google Scholar]
4. Chou C.K., Liu G.C., Chen L.T., Jaw T.S. The use of MRI in bowel obstruction. *Abdom. Imaging.* 1993;18:131–135. [PubMed] [Google Scholar]
5. Sasaya T, Yamaguchi A, Isogai M, Harada T, Kaneoka Y, Suzuki M. Supravesical hernia: CT diagnosis. *Abdom. Imaging.* 2001;26(January–February (1)):89e91. [PubMed] [Google Scholar]
6. Saravanan Balakrishnan. Supravesical hernia—a rare cause of intestinal obstruction. *Int. J. Surg.* 2016;6(6):471–472. [PubMed] [Google Scholar]
7. Mehran A, Szomstein S, Soto F, Rosenthal R. Laparoscopic repair of an internal strangulated supravesical hernia. *Surg. Endosc.* 2004;18(March (3)):554e6. [PubMed] [Google Scholar]
8. Koksoy FN., Soybir G.R., Bulut T.M., Yalcin O., Aker Y., Kose H. Internal supravesical hernia: report of a case. *Am. Surg.* 1995;61(November (11)):1023e4. [PubMed] [Google Scholar]